

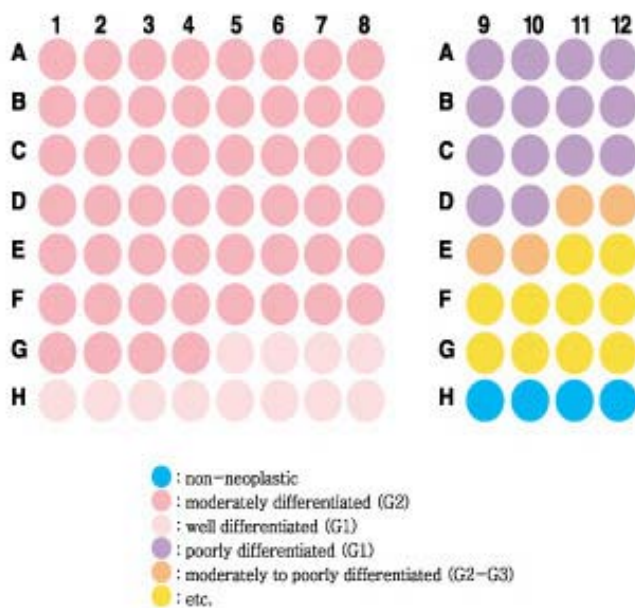
Specifications:

- No. of cases: 46
- Tissue type: Liver cancer tissues – Cholangiocarcinoma
- No. of spots: 2 spots from each cancer case (92 spots)
4 non-neoplastic spots (4 spots)
- Total spots: 96
- Corresponding normal tissues with cancers: No
- Diameter: 1.0 mm

Documents:

- Product specification: layout, summary of tissue spots
- H&E stained images
- Detailed pathological information

Layout:



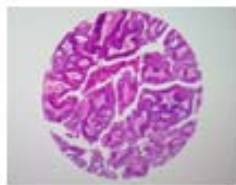Summary of tissue spot

No	Coordinate	Sex	Age	Key Word	Grade	TNM Stage	
1	A	1, 2	f	73	Cholangio ca.	G1	T1N0M0 (I)
2		3, 4	f	69	Cholangio ca.	G1	T2N0M0 (II)
3		5, 6	f	65	Cholangio ca.	G1	T3N0M0 (IIIA)
4		7, 8	f	68	Cholangio ca.	G1	T4N1MX (IIIC)
5		9, 10	f	73	Cholangio ca.	G2-G3	T2N0M1 (IV)
6		11, 12	f	65	Cholangio ca.	G2-G3	T3N1M1 (IV)
7	B	1, 2	f	49	Cholangio ca.	G1	T3N1M1 (IV)
8		3, 4	f	60	Cholangio ca.	G1	T3N0M1 (IV)
9		5, 6	f	52	Cholangio ca.	G2	T1N0M0 (I)
10		7, 8	f	73	Cholangio ca.	G2	T1N0M0 (I)
11		9, 10	f	55	Cholangio ca.	G3	T1N0M (I)
12		11, 12	f	47	Cholangio ca.	G3	T3N0M0 (IIIA)
13	C	1, 2	f	52	Cholangio ca.	G2	T2N0MX (II)
14		3, 4	f	76	Cholangio ca.	G2	T2N0M0 (II)
15		5, 6	f	59	Cholangio ca.	G2	T2N0M0 (II)
16		7, 8	f	56	Cholangio ca.	G2	T2N0M0 (II)
17		9, 10	f	74	Cholangio ca.	G3	T2N1M0 (IIC)
18		11, 12	f	55	Cholangio ca.	G3	T2N1M0 (IIIC)
19	D	1, 2	f	58	Cholangio ca.	G2	T2N0M0 (II)
20		3, 4	f	68	Cholangio ca.	G2	T3N0M0 (IIIA)
21		5, 6	f	61	Cholangio ca.	G2	T3N0M0 (IIIA)
22		7, 8	f	34	Cholangio ca.	G2	T3N0M0 (IIIA)
23		9, 10	f	52	Cholangio ca.	G3	T1N0M1 (IV)
24		11, 12	f	84	Cholangio ca.	G3	T3N0M1 (IV)
25	E	1, 2	f	69	Cholangio ca.	G2	T2N1M0 (IIIC)
26		3, 4	f	68	Cholangio ca.	G2	T3N1M0 (IIIC)
27		5, 6	f	73	Cholangio ca.	G2	T3N1M0 (IIIC)
28		7, 8	f	79	Cholangio ca.	G2	T3N1MX (IIIC)
29		9, 10	f	62	Cholangio ca.	G3	T3N1M1 (IV)
30		11, 12	f	83	Cholangio ca.	papillary adeno ca.	T1N0M0 (I)

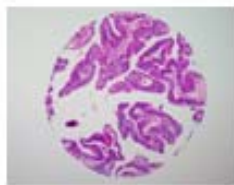Summary of tissue spot

No	Coordinate	Sex	Age	Key Word	Grade	TNM Stage	
31	F	1, 2	f	66	Cholangio ca.	G2	T2N1M0 (IIIC)
32		3, 4	f	56	Cholangio ca.	G2	T2N1M0 (IIIC)
33		5, 6	f	67	Cholangio ca.	G2	T2N1M1 (IV)
34		7, 8	f	40	Cholangio ca.	G2	T3N1M1 (IV)
35		9, 10	f	73	Cholangio ca.	papillary adeno ca.	T1NXM0 (I)
36		11, 12	f	69	Cholangio ca.	papillary cholangio ca.	T1N0M0 (I)
37	G	1, 2	f	63	Cholangio ca.	G2	T3N1M1 (IV)
38		3, 4	f	72	Cholangio ca.	G2	T2N0M1 (IV)
39		5, 6	f	56	Cholangio ca.	G2	T3N0M1 (IV)
40		7, 8	f	74	Cholangio ca.	G2	T3N1M1 (IV)
41		9, 10	f	64	Cholangio ca.	papillary cholangio ca.	T1N0M1 (IV)
42		11, 12	f	63	Cholangio ca.	combined hepatocellular - cholangio ca.	T1N0M0 (I)
43	H	1, 2	f	71	Cholangio ca.	G2	T3N1M1 (IV)
44		3, 4	f	74	Cholangio ca.	G2	T2N0M1 (IV)
45		5, 6	f	62	Cholangio ca.	G2	T2NXM1 (IV)
46		7, 8	f	65	Cholangio ca.	G2	T4NXM1 (IV)
47		9	f	57	Bile duct		
48		10	f	67	Bile duct		
49		11	m	57	Bile duct		
50		12	m	64	Bile duct		

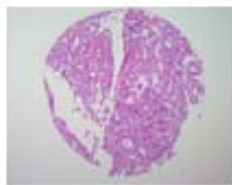
QC sheet_LOT#122120310201
Hematoxylin and Eosin staining



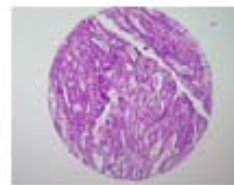A1



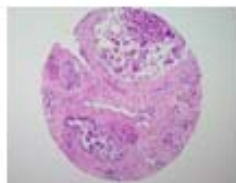
A2



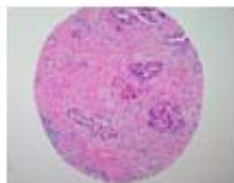
A3



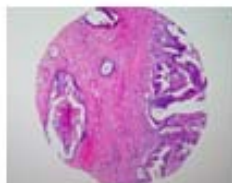A4



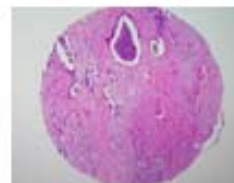A5



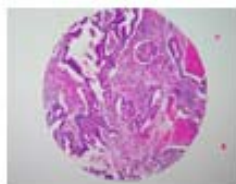
A6



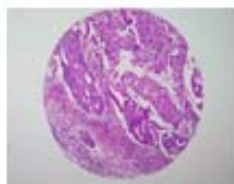
A7



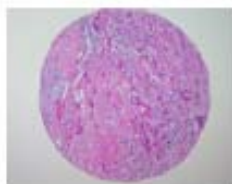
A8



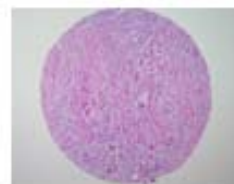A9



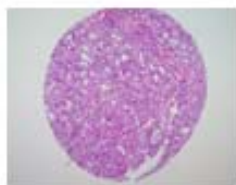
A10



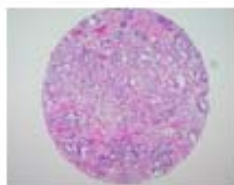
A11



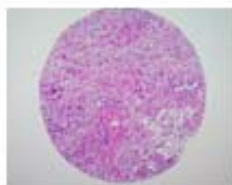
A12



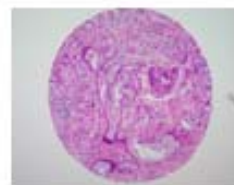B1



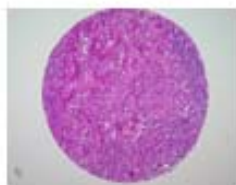B2



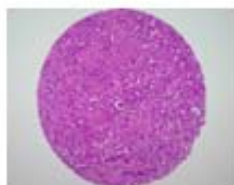
B3



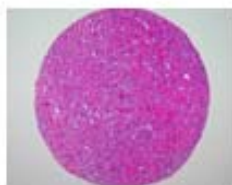B4



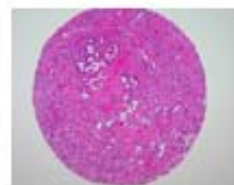B5



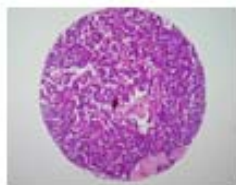
B6



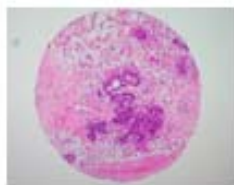
B7



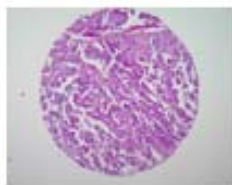
B8



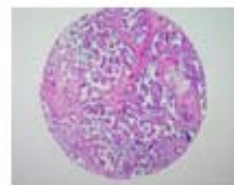
B9



B10

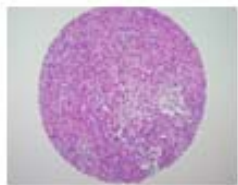


B11

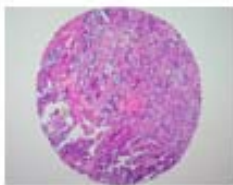


B12

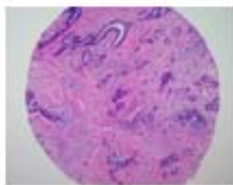
QC sheet_LOT#122120310201
Hematoxylin and Eosin staining



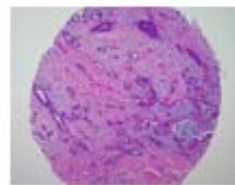
C1



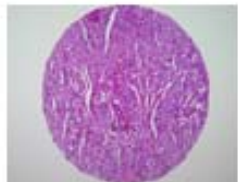C2



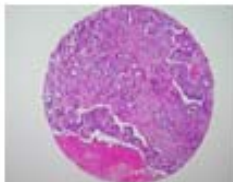
C3



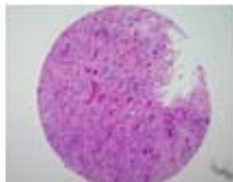
C4



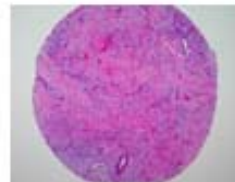
C5



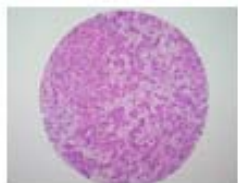
C6



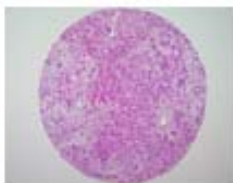
C7



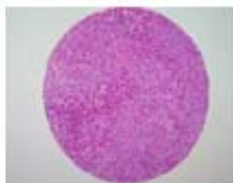C8



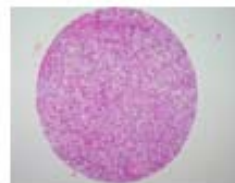C9



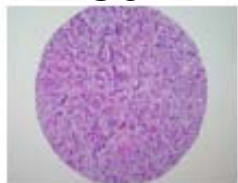C10



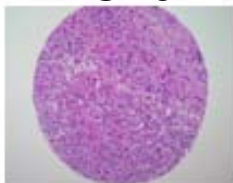C11



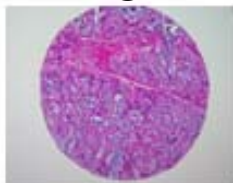C12



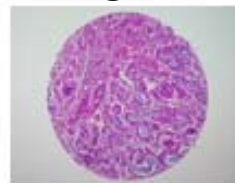D1



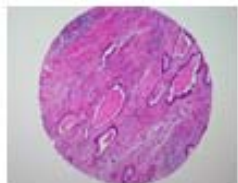D2



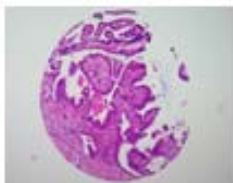D3



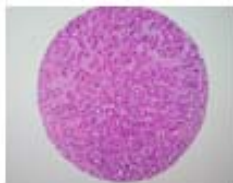D4



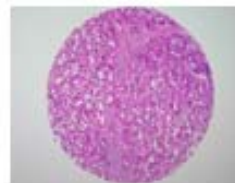D5



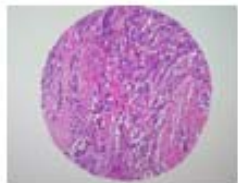D6



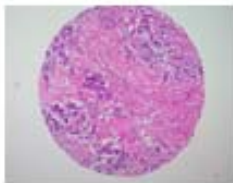
D7



D8



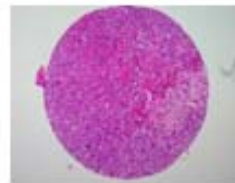
D9



D10

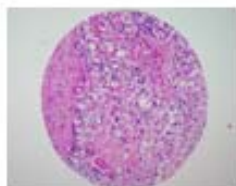

D11

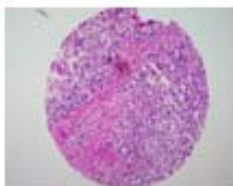


D12

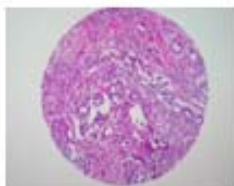
QC sheet_LOT#122120310201
Hematoxylin and Eosin staining



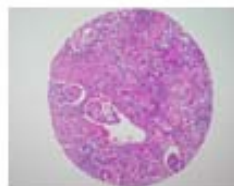
E1



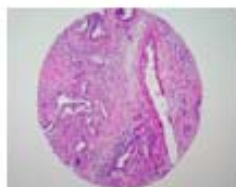
E2



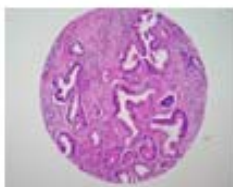
E3



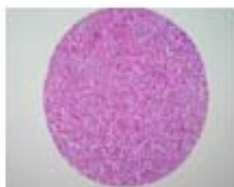E4



E5



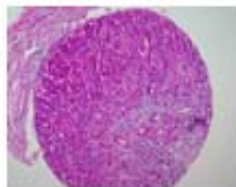
E6



E7



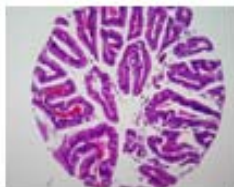E8



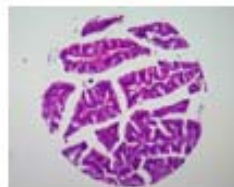E9



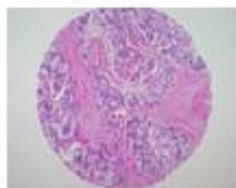
E10



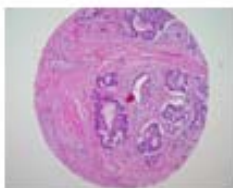E11



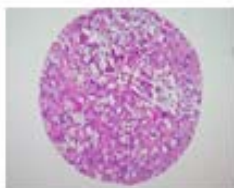
E12



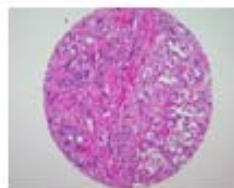
F1



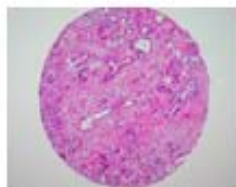
F2



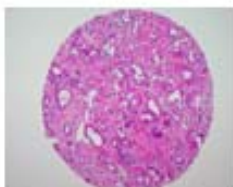
F3



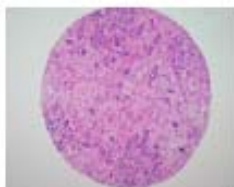
F4



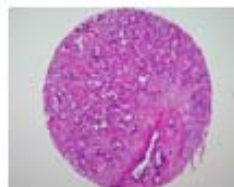F5



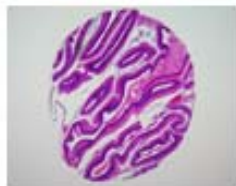F6



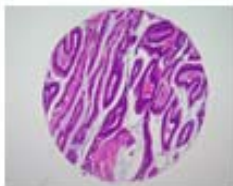F7



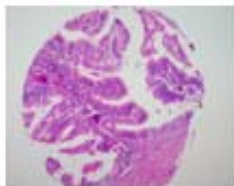
F8



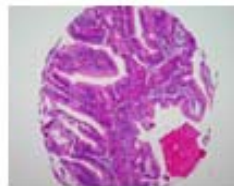
F9



F10

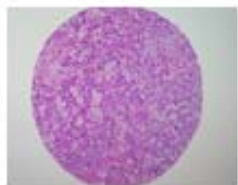

F12



F12

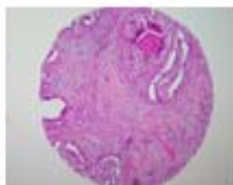
QC sheet_LOT#122120310201
Hematoxylin and Eosin staining



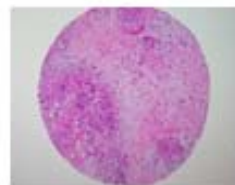
G1



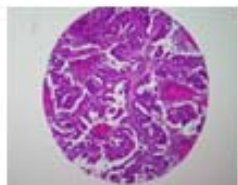
G2



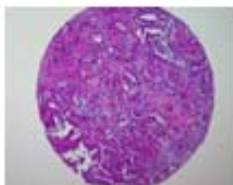
G3



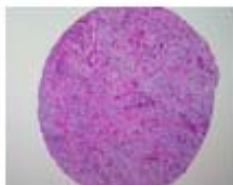
G4



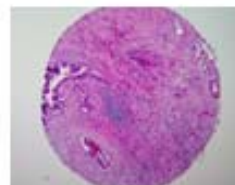
G5



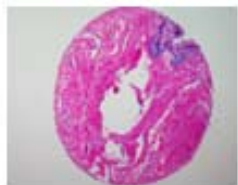G6



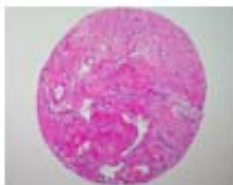
G7



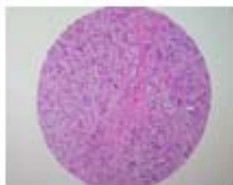G8



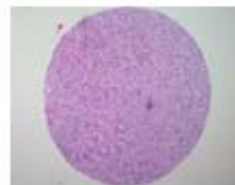G9



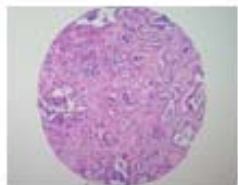
G10



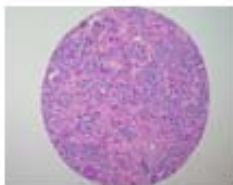
G11



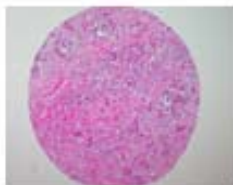
G12



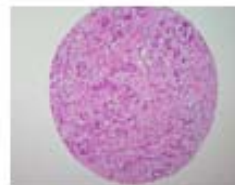
H1



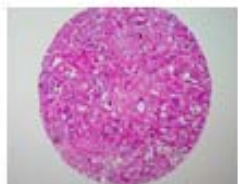H2



H3



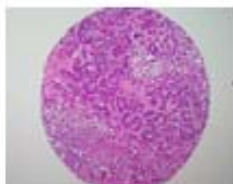H4



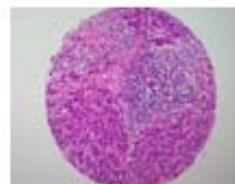
H5



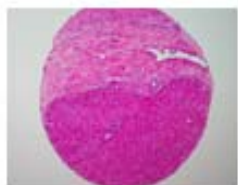
H6



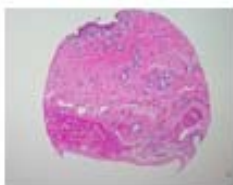
H7



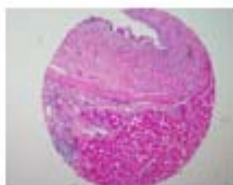
H8



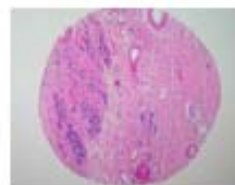
H9



H10



H11



H12

A205: Liver cancer tissues - cholangiocarcinoma

No.	Coordinate	Sex	Age	Key Word	Histological Diagnosis	Grade	TNM Stage
1	A 1, 2	f	73	cholangio ca.	<p>1. Liver, segmentectomy: Cholangiocarcinoma, well differentiated</p> <ol style="list-style-type: none"> 1) predominant papillary growth pattern 2) accompanying fibrosis, acute and chronic nonspecific inflammation with abscess foam cell infiltration and granuloma formation 3) resection margin, capsule: free of tumor <p>2. Remaining liver: nonspecific reactive hepatitis with</p> <ol style="list-style-type: none"> 1) predominant periductal fibrosis and ductular proliferation 2) epithelial hyperplasia of large duct and mural gland proliferation, clonorchiasis 	G1	T1N0M0 (I)
2	A 3, 4	f	69	cholangio ca.	<p>1. Liver, left lobectomy: Cholangiocarcinoma, hilar, well differentiated with polypoid gross type</p> <ol style="list-style-type: none"> 1) invasion to periductal soft tissue 2) resection margin, bile duct: extension of the tumor 3) resection margin, liver: free of tumor <p>2. Remaining liver: marked dilatation of intrahepatic bile duct with</p> <ol style="list-style-type: none"> 1) periductal fibrosis, chronic nonspecific inflammation and mural gland proliferation 2) portal fibrosis with chronic inflammation and bile ductular proliferation <p>3. Gallbladder, cholecystectomy: chronic nonspecific inflammation</p>	G1	T2N0M0 (II)

A205: Liver cancer tissues - cholangiocarcinoma

No.	Coordinate		Sex	Age	Key Word	Histological Diagnosis	Grade	TNM Stage
3	A	5, 6	f	65	cholangio ca.	<p>1. Liver including common hepatic duct, trisegmentectomy and cholecystectomy: Cholangiocarcinoma, hilar, well differentiated with</p> <ol style="list-style-type: none"> 1) involvement of common hepatic duct, right and left hepatic duct 2) frequent perineural invasion 3) a few vascular involvement <p>2. Remaining liver: Portal fibrosis with ductular proliferation</p> <ol style="list-style-type: none"> 1) resection margin, left hepatic duct: extension of adenocarcinoma 2) resection margin, common bile duct, liver: free of tumor <p>3. Soft tissue, labelled as segment II : adenocarcinoma, well differentiated</p> <p>4. Gallbladder: Chronic nonspecific inflammation</p> <ol style="list-style-type: none"> 1) regional lymph noe, No.8 (0/6), No.12 (0/3), No.13 (0/1), site unstated (0/4), regional (0/1) : (0/15) : free of tuomor 	G1	T3N0M0 (IIIA)
4	A	7, 8	f	68	cholangio ca.	<p>1. Liver, right, lobectomy: cholangiocarcinoma, well differentiated, hilar with</p> <ol style="list-style-type: none"> 1) extension to the Glisson's capsule 2) eumerous lymphatic, perineural and neural invasion 3) mmucin production 4) multifocal abscess formation showing acute inflammatory cells and macrophages admixed with eggs of clonorchis sinensis 5) resection margin liver: free of tumor <p>2. Bile duct:</p> <ol style="list-style-type: none"> 1) severe cautery artifact with mural gland proliferation 2) no evidence of adenocarcinoma 3) regional lymph nodes, hilar (1/1), LN9 (2/2): tumor metastasis in all 3/3 lymph nodes 4) adenocarcinoma with perineural invasion into the wall 5) papillary epithelial hyperplasia and dysplasia <p>3. Soft tissue, labelled as "portal vein tumor": presence of adenocarcinoma</p> <ol style="list-style-type: none"> 1) soft tissue, labelled as "periportal lymphatic invasion": presence of adenocarcinoma <p>4. Gallbladder: chronic nonspecific inflammation</p>	G1	T4N1MX (IIIC)

A205: Liver cancer tissues - cholangiocarcinoma

No.	Coordinate		Sex	Age	Key Word	Histological Diagnosis	Grade	TNM Stage
5	A	9, 10	f	73	cholangio ca.	<p>1. Liver, left lateral segment, segmentectomy: Cholangiocarcinoma, moderate to poorly differentiated, peripheral type with</p> <ol style="list-style-type: none"> 1) size: 6x5.5x5 cm 2) vascular invasion 3) intact intrahepatic resection margin (safety margin: 0.7 mm) 4) non-neoplastic liver showing reactive hepatitis <p>2. Gallbladder, cholecystectomy: free from tumor extension</p>	G2-G3	T2N0M1 (IV)
6	A	11, 12	f	65	cholangio ca.	<p>Liver, right lobe, lobectomy: Cholangiocarcinoma, moderately differentiated to poorly differentiated peripheral type with</p> <ol style="list-style-type: none"> 1) size: 6.5x6x4 cm 2) expanding growth pattern 3) extension to perihilar soft tissue and gallbladder 4) perineural and vascular invasions 5) intact bile duct and intrahepatic resection margin 6) intrahepatic metastasis 7) metastasis to 1 out of 11 regional lymph nodes (perihilar (0/2), no.8 (0/4), no.9 (1/3), no.12 (0/2), and no.12a (0/2)) 8) nonneoplastic liver showing mild cholestasis 	G2-G3	T3N1M1 (IV)

A205: Liver cancer tissues - cholangiocarcinoma

No.	Coordinate	Sex	Age	Key Word	Histological Diagnosis	Grade	TNM Stage
7	B 1, 2	f	49	cholangio ca.	<p>1. Liver, S4,5,8, central lobectomy: Cholangiocarcinoma with squamous differentiation (adenosquamous carcinoma) with</p> <ol style="list-style-type: none"> 1) frequent lymphatic and portal vein invasion 2) invasion to Glisson's capsule 3) invasion to wall of hepatic artery 4) resection margin: free of tumor <p>2. Remaining liver: epithelial hyperplasia of bile duct with Mural gland proliferation, possibly due to clonorchis sinensis</p> <ol style="list-style-type: none"> 1) lymph nodes, labelled as No.8 (1/1), No.13 (1/1), regional (1/1) : (3/3): metastatic carcinoma in all lymph nodes <p>3. Soft tissue, labelled as diaphragm: adenosquamous carcinoma, metastatic</p> <ol style="list-style-type: none"> 1) soft tissue, labelled as pelvic peritoneum: adenosquamous carcinoma, metastatic <p>4. Gallbladder, cholecystectomy: autolysis with mild chronic nonspecific inflammation</p>	G1	T3N1M1 (IV)
8	B 3, 4	f	60	cholangio ca.	<p>1. Liver and common bile duct, right trisegmentectomy: Cholangiocarcinoma, well differentiated, hilar with</p> <ol style="list-style-type: none"> 1) involvement of common hepatic duct, right hepatic duct and part of left hepatic duct 2) frequent perineural and neural involvement <p>2. Remaining liver: non-specific reactive hepatitis with marked ductal proliferation and portal fibrosis</p> <p>3. Gallbladder, cholecystectomy: chronic nonspecific inflammation</p> <ol style="list-style-type: none"> 1) resection margin, proximal and distal: free of tumor 2) regional lymph node, pericommmon hepatic duct (0/2), No.8 (0/3), No.12 (0/4), No.13 (0/1): free of tumor in all 10 nodes 	G1	T3N0M1 (IV)

A205: Liver cancer tissues - cholangiocarcinoma

No.	Coordinate		Sex	Age	Key Word	Histological Diagnosis	Grade	TNM Stage
9	B	5, 6	f	52	cholangio ca.	<p>1. Liver, segmentectomy: Cholangiocarcinoma, peripheral, moderately differentiated with</p> <ol style="list-style-type: none"> 1) confined to liver parenchyma 2) Glisson's capsule: fibrosis without tumor invasion 3) neutrophilic infiltration 4) no lymphovascular or perineural invasion <p>2. Remaining liver: Chronic hepatitis, active, said to be B-viral</p> <ol style="list-style-type: none"> 1) resection margin: free of tumor <p>3. Gallbladder, cholecystectomy: autolysis</p>	G2	T1N0M0 (I)
10	B	7, 8	f	73	cholangio ca.	<p>1. Liver and hepatic duct, trisegmentectomy: Cholangiocarcinoma, adenocarcinoma, moderately differentiated, hilar type (Klatskin tumor) with</p> <ol style="list-style-type: none"> 1) size: 2 cm in the greatest dimension 2) infiltrative growth 3) extension to perihilar soft tissue and liver 4) frequent perineural invasion 5) involvement at right hepatic resection margin 6) intact resection margins of liver and common bile duct 7) no metastasis to regional lymph nodes (No.1 (0/2) and No.2 (0/2)) 8) non-neoplastic liver showing biliary cirrhosis with marked cholestasis 9) chronic cholecystitis without tumor metastasis in gallbladder 	G2	T1N0M0 (I)
11	B	9, 10	f	55	cholangio ca.	<p>1. Liver, right, lobectomy: Cholangiocarcinoma, with focal hepatoid feature with</p> <ol style="list-style-type: none"> 1) size: 7.5x7x6.5 cm 2) poorly differentiated 3) expanding growth and intact hepatic resection margin (safety margin: about 1 mm) 4) capsular involvement 5) non neoplastic liver showing reactive hepatitis <p>2. Gallbladder: free from tumor extension</p>	G3	T1N0M (I)

A205: Liver cancer tissues - cholangiocarcinoma

No.	Coordinate		Sex	Age	Key Word	Histological Diagnosis	Grade	TNM Stage
12	B	11, 12	f	47	cholangio ca.	<p>1. Liver, right, lobectomy: Cholangiocarcinoma, poorly differentiated, with</p> <p>1) prominent clear cell change and marked necrosis, showing prominent vascular permeation and involving capsule with extension into adhered pericapsular fat tissue</p> <p>2) resection margin: free of tumor</p> <p>2. Gallbladder: chronic nonspecific inflammation</p> <p>Note: Result of immunohistochemistry: Cytokeratin 7 (+), Cytokeratin 20 (-), CEA (-), AFP(equivocal).</p>	G3	T3N0M0 (IIIA)
13	C	1, 2	f	52	cholangio ca.	<p>1. Liver, right lobectomy: Cholangiocarcinoma, hilar, moderately differentiated with</p> <p>1) involvement of right and left hepatic duct and common hepatic duct</p> <p>2) frequent perineural and neural invasion</p> <p>3) extension to soft tissue around common hepatic duct</p> <p>4) Glisson's capsule: free of tumor</p> <p>5) resection margin, left hepatic duct, common bile duct and liver : free of tumor</p> <p>2. Remaining liver: the additional report will follow</p>	G2	T2N0MX (II)

A205: Liver cancer tissues - cholangiocarcinoma

No.	Coordinate		Sex	Age	Key Word	Histological Diagnosis	Grade	TNM Stage
14	C	3, 4	f	76	cholangio ca.	<p>1. Liver, right lobectomy: Cholangiocarcinoma, hilar, moderately differentiated with</p> <ol style="list-style-type: none"> 1) involvement of the whole wall of common hepatic duct right and left hepatic duct 2) extensive perineural invasion 3) severe desmoplasia <p>2. Remaining liver: Reactive atypia of bile duct epithelium, with</p> <ol style="list-style-type: none"> 1) periductal concentric fibrosis 2) multifocal periductal abscess formation with resolution 3) massive ischemic necrosis 4) central cholestasis with mild microvascular fatty change 5) resection margin, left hepatic duct, common bile duct: extension of tumor <p>3. Soft tissue, labelled as LN8: nerves with adipose tissue without extension of tumor</p> <p>4. Adipose tissue, labelled as left hepatic artery: free of tumor</p> <p>5. Gallbladder, cholecystectomy:</p> <ol style="list-style-type: none"> 1) marked autolysis 2) free of tumor 	G2	T2N0M0 (II)
15	C	5, 6	f	59	cholangio ca.	<p>1. Liver, left, lobectomy: Cholangiocarcinoma, peripheral, moderately differentiated with</p> <ol style="list-style-type: none"> 1) Glisson's capsule: free of tumor 2) occasional lymphatic permeation 3) resection margin: free of tumor <p>2. Remaining liver: periductal fibrosis with</p> <ol style="list-style-type: none"> 1) mural gland proliferation 2) fatty change macro and micro vesicular, 1+ 3) regional lymph nodes, No.8 (0/7), No.9 (0/5): free of tumor in all 12 nodes 	G2	T2N0M0 (II)

A205: Liver cancer tissues - cholangiocarcinoma

No.	Coordinate		Sex	Age	Key Word	Histological Diagnosis	Grade	TNM Stage
16	C	7, 8	f	56	cholangio ca.	<p>1. Liver, right lobe, lobectomy: Cholangiocarcinoma, hilar, moderately differentiated, with</p> <ol style="list-style-type: none"> 1) involvement of right hepatic duct and common hepatic duct 2) frequent perineural invasion 3) occasional vascular invasion 4) Glisson's capsule: free of tumor <p>2. Remaining liver: multifocal at periductal abscess formation with fibrosis</p> <ol style="list-style-type: none"> 1) resection margin, liver: free of tumor 2) resection margin, common bile duct: epithelial hyperplasia with dysplasia 3) resection margin, left hepatic duct: epithelial hyperplasia <p>3. Blood vessel labelled as bile duct: free of tumor</p> <ol style="list-style-type: none"> 1) lymph nodes, N8 (0/3), N12p (0/9), N13 (0/2), unlabelled lymph node (0/1), 2) pericholedocal lymph node (0/1) : (0/16): free of tumor <p>4. Gallbladder, cholecystectomy: chronic nonspecific inflammation</p>	G2	T2N0M0 (II)
17	C	9, 10	f	74	cholangio ca.	<p>1. Liver, left, lobectomy: Cholangiocarcinoma, intrahepatic, poorly differentiated with</p> <ol style="list-style-type: none"> 1) intrahepatic lymphatics, perineural and intraneural and capsular invasion 2) resection margin, liver: free of tumor <p>2. Gallbladder: no pathological diagnosis</p> <p>3. Bile duct, resection margin: lymphatic invasion of tumor and capsular invasion</p>	G3	T2N1M0 (IIC)

A205: Liver cancer tissues - cholangiocarcinoma

No.	Coordinate		Sex	Age	Key Word	Histological Diagnosis	Grade	TNM Stage
18	C	11, 12	f	55	cholangio ca.	<p>1. Liver, central lobectomy with lymph node dissection: Cholangiocarcinoma, poorly differentiated, peripheral with</p> <ol style="list-style-type: none"> 1) confined to the liver parenchyma. 2) Glisson's capsule: free of tumor 3) frequent lymphatic and venous invasion 4) occasional perineural invasion <p>2. Remaining liver: multiple abscess formation with</p> <ol style="list-style-type: none"> 1) periductal fibrosis and mural gland proliferation 2) resection margin: extension of tumor <p>3. Gallbladder: Chronic nonspecific inflammation</p> <ol style="list-style-type: none"> 1) lymph nodes, No.8 (1/1), No.12P (1/1), No.12B (1/1), unlabelled (0/3) : (3/6): metastatic carcinoma 	G3	T2N1M0 (IIIC)
19	D	1, 2	f	58	cholangio ca.	<p>1. Liver and gallbladder, right, lobectomy and cholecystectomy: Cholangiocarcinoma, moderately differentiated, peripheral type with</p> <ol style="list-style-type: none"> 1) size: 4.8x4x4 cm 2) expanding growth 3) invasion to perihilar fibroadipose tissue and hepatic capsule 4) perineural and microvascular invasions 5) intact resection margin 6) non-neoplastic liver showing irregularly widened bridging fibrosis and prominent ductular proliferation approaching to biliary cirrhosis <p>2. Gallbladder, cholecystectomy: autolysis without tumor metastasis</p>	G2	T2N0M0 (II)

A205: Liver cancer tissues - cholangiocarcinoma

No.	Coordinate		Sex	Age	Key Word	Histological Diagnosis	Grade	TNM Stage
20	D	3, 4	f	68	cholangio ca.	<p>1. Liver, segmentectomy: Cholangiocarcinoma with</p> <ol style="list-style-type: none"> 1) partly spindle cell metaplasia, with portal vein invasion and capsular invasion 2) sclerosing hepatocellular carcinoma, moderately differentiated, trabecular and acinus type 3) liver cirrhosis, macronodular 4) biliary hyperplasia and cholangitis <p>2. Gallbladder: no pathological diagnosis</p>	G2	T3N0M0 (IIIA)
21	D	5, 6	f	61	cholangio ca.	<p>1. Liver including hepatic duct and common bile duct, left lobectomy and hepatic duct resection: Cholangiocarcinoma, hilar (Klatskin tumor), moderately differentiated with</p> <ol style="list-style-type: none"> 1) involvement of common bile duct, left hepatic duct and part of right hepatic duct 2) extensive perineural invasion 3) Invasion of portal vein and tumor thrombi formation 4) ischemic necrosis with hyalinization 5) frequent lymphatic formation <p>2. Remaining liver: Central ischemic necrosis with ductular cholestasis</p> <ol style="list-style-type: none"> 1) multifocal eosinophilic infiltration with granuloma 2) resection margin, liver: free of tumor 3) resection margin, right hepatic duct: extension of carcinoma 4) resection margin, common bile duct: marked erosion with chronic nonspecific inflammation <p>3. Gallbladder, cholecystectomy: chronic cholecystitis with cholelithiasis</p>	G2	T3N0M0 (IIIA)

A205: Liver cancer tissues - cholangiocarcinoma

No.	Coordinate		Sex	Age	Key Word	Histological Diagnosis	Grade	TNM Stage
22	D	7, 8	f	34	cholangio ca.	<p>1. Liver, right, lobectomy: Cholangiocarcinoma, peripheral type with</p> <ol style="list-style-type: none"> 1) size: 12x11x10 cm 2) expanding growth 3) invasion to portal vein 4) no involvement of intrahepatic resection margin (safety margin: less than 0.5 cm) 5) nonneoplastic liver showing reactive hepatitis with marked cholestasis <p>2. Soft tissue, hilum, separately submitted: free from tumor extension</p> <p>3. Bile duct, separately submitted: free from tumor extension</p> <p>4. Gallbladder, cholecystectomy, separately submitted: free from tumor extension</p> <ol style="list-style-type: none"> 1) lymph nodes, regional (pericolonic (0/1), and No.8 (0/2) and 12 (0/1): free from tumor extension 	G2	T3N0M0 (IIIA)
23	D	9, 10	f	52	cholangio ca.	<p>1. Liver, left lobe: Cholangiocarcinoma, poorly differentiated, with</p> <ol style="list-style-type: none"> 1) necrosis and nerve invasion 2) Intrahepatic stones, multiple 3) resection margin, positive of tumor extension 4) lymph node, paracaval: free of tumor <p>2. Gallbladder: gallstones</p> <ol style="list-style-type: none"> 1) autolysis of the mucosa 	G3	T1N0M1 (IV)

A205: Liver cancer tissues - cholangiocarcinoma

No.	Coordinate		Sex	Age	Key Word	Histological Diagnosis	Grade	TNM Stage
24	D	11, 12	f	84	cholangio ca.	1. Liver, excision: cholangiocarcinoma, peripheral, poorly differentiated with 1) necrosis about 50% 2) involvement of Glisson's capsule 3) many portal vein tumor thrombi 4) occasional lymphatic permeation 5) resection margin: extension of tumor 2. Remaining liver: nonspecific reactive hepatitis with periductal concentric 1) fibrosis in the portal tracts 2) nuclear glycogenosis 3. Soft tissue, labelled as perigastric lymph node: metastatic adenocarcinoma 4. Gallbladder, cholecystectomy: chronic nonspecific inflammation without evidence of tumor	G3	T3N0M1 (IV)
25	E	1, 2	f	69	cholangio ca.	1. Liver: Invasion of adenocarcinoma 1) abscess formation due to cholangitis 2) cholangitis and cholestasis due to obstruction of bile duct 3) bile ductular proliferation 4) liver cell necrosis and cholestasis 2. Intrahepatic bile duct: adenocarcinoma, moderately well differentiated (clinically klatskin tumor, cholangiocarcinoma) with 1) vascular invasion and neural invasion 2) interhepatic duct, resection margin: extension of adenocarcinoma 3) periportal, resection margin: extension of adenocarcinoma 4) lymph nodes, n8 and n12 (4/13), n12 (1/5): metastatic carcinoma	G2	T2N1M0 (IIIC)

A205: Liver cancer tissues - cholangiocarcinoma

No.	Coordinate	Sex	Age	Key Word	Histological Diagnosis	Grade	TNM Stage
26	E 3, 4	f	68	cholangio ca.	<p>1. Liver, left lobe, lobectomy: Cholangiocarcinoma, hilar, moderately differentiated with</p> <ol style="list-style-type: none"> 1) involvement of whole wall of the common hepatic duct, left hepatic duct and part of right hepatic duct, see note 2) frequent perineural invasion 3) frequent venous invasion 4) invasion to the wall of portal vein 5) multifocal necrosis and abscess formation 6) severe desmoplasia 7) resection margin, common bile duct, right hepatic duct: free of tumor 8) lymph nodes, No.8 (1/1), No.12 (1/4), No.13 (0/11) : (2/16): metastatic carcinoma in 2 out of 16 lymph nodes 	G2	T3N1M0 (IIIC)
27	E 5, 6	f	73	cholangio ca.	<p>1. Liver, left, lobectomy: Cholangiocarcinoma, hilar, moderately differentiated, with</p> <ol style="list-style-type: none"> 1) involvement of right hepatic duct and common hepatic duct 2) frequent perineural and neural invasion 3) portal vein invasion 4) occasional vascular invasion 5) severe desmoplasia 6) resection margin, common bile duct, liver, right intrahepatic duct: free of tumor 7) regional lymph nodes, N8 (3/3), N12 (0/3) : (3/6): tumor metastasis in 3 out of 6 lymph nodes <p>2. Gallbladder, cholecystectomy: chronic nonspecific inflammation with autolysis</p>	G2	T3N1M0 (IIIC)

A205: Liver cancer tissues - cholangiocarcinoma

No.	Coordinate		Sex	Age	Key Word	Histological Diagnosis	Grade	TNM Stage
28	E	7, 8	f	79	cholangio ca.	<p>1. Liver, lobectomy: Cholangiocarcinoma, peripheral, moderately differentiated with</p> <ol style="list-style-type: none"> 1) invasion to Glisson's capsule and perimuscular soft tissue of gallbladder 2) frequent perineural invasion 3) occasional lymphatic permeation 4) non neoplastic liver: dilatation of sinusoid and congestion 5) resection margin: Invasion of cholangiocarcinoma <p>2. Gallbladder: autolysis</p> <ol style="list-style-type: none"> 1) tumor invasion in the perimuscular soft tissue 2) lymph nodes, LN8 (3/4), LN12 (3/3): tumor metastasis in 6 out of 7 lymph nodes 	G2	T3N1MX (IIIC)
29	E	9, 10	f	62	cholangio ca.	<p>1. Liver, segments IV, V, segmentectomy: Cholangiocarcinoma, poorly differentiated, arising from major hepatic duct of the hilar area with</p> <ol style="list-style-type: none"> 1) size: 11x8 cm 2) infiltrative growth with multiple intrahepatic metastasis 3) frequent lymphovascular and perineural invasion 4) diffuse invasion to hepatic capsule, bile duct, duodenum, diaphragm, and surrounding soft tissue 5) extension to resection margins of the bile ducts 6) metastasis to lymph node (separately submitted) 7) non-neoplastic liver showing reactive hepatitis 	G3	T3N1M1 (IV)

A205: Liver cancer tissues - cholangiocarcinoma

No.	Coordinate	Sex	Age	Key Word	Histological Diagnosis	Grade	TNM Stage
30	E 11, 12	f	83	cholangio ca.	<p>1. Liver, left lobe, lobectomy: Cholangiocarcinoma, peripheral, intraductal variant with</p> <ol style="list-style-type: none"> 1) multiple papillary mass formation 2) spread to mural glands 3) no definite invasion to stroma 4) intestinal metaplasia and mucosal severe dysplasia in the remaining intrahepatic bile ducts 5) Glisson's capsule: free of tumor 6) resection margin, hepatic duct: extension of carcinoma <p>2. Remaining liver: intrahepatic duct stone with ductal dilatation,</p> <ol style="list-style-type: none"> 1) mural gland feration and periductal fibrosis 2) multifocal abscess formation (primary recurrent pyogenic cholangitis) 3) nonspecific reactive hepatitis showing portal inflammation, fibrosis and mild mural gland proliferation <p>3. Gallbladder, cholecystectomy: Chronic nonspecific inflammation with</p> <ol style="list-style-type: none"> 1) rokitanskry-aschoff sinuses formation and pyloric gland metaplasia 2) lymph node, clinically from segment v (0/2): free of tumor <p>4. Intrahepatic duct, left, separately sent: papillary epithelial hyperplasia with dysplasia</p>	papillary adeno ca.	T1N0M0 (I)
31	F 1, 2	f	66	cholangio ca.	<p>1. Liver, right, lobectomy: Cholangiocarcinoma, moderately differentiated, peripheral type and dense fibrosis</p> <ol style="list-style-type: none"> 1) size: 6x4 cm 2) penetration of capsule and infiltration into diaphragm and lung 3) vascular and frequent perineural invasion 4) intact resection margin (less than about 1 mm from tumor) 5) intrahepatic metastasis <p>2. Gallbladder: free of tumor</p> <p>3. Lung, separately sent: extension of tumor</p> <ol style="list-style-type: none"> 1) lymph nodes, separately sent, N8 (0/5), N9 (3/5), N12 (0/1): tumor metastasis in 3 out of 11 lymph nodes 	G2	T2N1M0 (IIIC)

A205: Liver cancer tissues - cholangiocarcinoma

No.	Coordinate		Sex	Age	Key Word	Histological Diagnosis	Grade	TNM Stage
32	F	3, 4	f	56	cholangio ca.	<p>1. Liver, right, lobectomy: Cholangiocarcinoma, hilar type (klaskin tumor), moderately differentiated with</p> <ol style="list-style-type: none"> 1) size: 3x2.5x2 cm 2) expansive growth into liver 3) lymphovascular and perineural invasion 4) clear resecton margin of liver (less than 0.1 mm apart from tumor) and common bile duct 5) tumor metastasis to 4 out of 16 periductal lymph nodes (periducta I (1/1), NO.8 (2/5), No.9 (0/6), No.12 (1/4)) 6) non-neoplastic liver showing marked cholestasis due to major intrahepatic duct obstruction <p>2. Gallbladder and cystic duct: free from tumor extension</p>	G2	T2N1M0 (IIIC)
33	F	5, 6	f	67	cholangio ca.	<p>1. Liver, rt lobectomy: Intrahepatic cholangiocarcinoma (3.5 cm)</p> <ol style="list-style-type: none"> 1) intrahepatic bile duct dilatation with marked 2) subacute and granulomatous cholangitis <p>2. Gallbladder, cholecystectomy: chronic cholecystitis with cholelithiasis</p> <ol style="list-style-type: none"> 1) resection margin: focal atypia of bile duct epithelium, extensive cauterization artefacts make it impossible to determine the status of the resection margin 2) In 13: metastatic cholangiocarcinoma in the lymph node 3) In 9': fibrofatty tissue containing nerve fiber fascicles and vessels 4) In 8: benign reactive lymph nodes 5) 'perigastric In': benign fibrofatty tissue 	G2	T2N1M1 (IV)

A205: Liver cancer tissues - cholangiocarcinoma

No.	Coordinate		Sex	Age	Key Word	Histological Diagnosis	Grade	TNM Stage
34	F	7, 8	f	40	cholangio ca.	<p>1. Liver, left, extended lobectomy: Cholangiocarcinoma, tubular adenocarcinoma, moderately differentiated with</p> <ol style="list-style-type: none"> 1) extensive lymphatic permeation and perineural invasion 2) resection margin, liver, extension of tumor 3) resection margin, proximal, left hepatic duct extension of tumor 4) resection margin, distal, common bile duct, free of tumor regional lymph node, around cystic duct, (0/1), free of tumor regional lymph node, omentum, separately submitted, (1/1), metastatic adenocarcinoma 5) soft tissue of omentum, perineural invasion of tumor <p>2. Gallbladder, cholecystectomy: chronic nonspecific inflammation</p>	G2	T3N1M1 (IV)
35	F	9, 10	f	73	cholangio ca.	<p>1. Liver, left, lobectomy: Intrahepatic duct stone with</p> <ol style="list-style-type: none"> 1) papillary epithelial hyperplasia, Intestinal metaplasia, severe dysplasia and focal carcinomatous change of biliary epithelium (cholangiocarcinoma, peripheral, Intraductal variant) 2) no invasion to periductal stroma <p>3. Remaining liver: nonspecific reactive hepatitis</p> <ol style="list-style-type: none"> 1) resection margin: presence of moderate epithelial dysplasia in the biliary epithelium 	papillary adeno ca.	T1NXM0 (I)

A205: Liver cancer tissues - cholangiocarcinoma

No.	Coordinate	Sex	Age	Key Word	Histological Diagnosis	Grade	TNM Stage
36	F 11, 12	f	69	cholangio ca.	<p>1. Liver, left, lobectomy: Intraductal papillary cholangiocarcinoma with 1) involvement of common hepatic duct, left hepatic duct with its segmental branches and part of right hepatic duct 2) focal invasion 3) resection margin, common hepatic duct: free of tumor 4) resection margins, right hepatic duct, anterior and posterior branch: presence of dysplasia with papillary change</p> <p>4. Remaining liver: Massive periductal concentric fibrosis 1) chronic nonspecific inflammation and parenchymal atrophy 2) previous history of clonorchis sinensis infection</p> <p>5. Caudate lobe: presence of intraductal papillary cholangiocarcinoma without invasion</p> <p>6. Gallbladder: free of tumor 1) lymph node, labelled as "LN8": free of tumor in all are lymph node</p>	papillary cholangio ca.	T1N0M0 (I)
37	G 1, 2	f	63	cholangio ca.	<p>1. Liver, left, lobectomy: Cholangiocarcinoma, moderately differentiated with 1) multifocal necrosis 2) extensive perineural and neural invasion 3) several satellite nodules 4) capsule extension of the tumor without penetration 5) resection margin: extension of the tumor</p> <p>2. Remaining liver: Non-specific reactive hepatitis</p> <p>3. Caudate lobe: cholangiocarcinoma with extension to the resection margin 1) lymph nodes, No.1 (1/1), No.8 (3/3), hilar LN (1/1) : metastatic cholangiocarcinoma in 5 out of 5 nodes</p> <p>4. Gallbladder: chronic nonspecific inflammation</p> <p>5. Clonorchis sinensis, separately submitted</p>	G2	T3N1M1 (IV)

A205: Liver cancer tissues - cholangiocarcinoma

No.	Coordinate		Sex	Age	Key Word	Histological Diagnosis	Grade	TNM Stage
38	G	3, 4	f	72	cholangio ca.	<p>1. Liver, segment III and IV, segmentectomy: Cholangiocarcinoma, moderately differentiated with</p> <ol style="list-style-type: none"> 1) peripheral type 2) necrosis about 30% 3) involvement of Glisson's capsule 4) frequent perineural invasion 5) resection margin: free of tumor <p>2. Remaining liver: nonspecific reactive hepatitis</p>	G2	T2N0M1 (IV)
39	G	5, 6	f	56	cholangio ca.	<p>1. Liver, right, lobectomy: Cholangiocarcinoma, peripheral type moderately differentiated with</p> <ol style="list-style-type: none"> 1) necrosis about 30% 2) tumor thrombi in portal vein 3) invasion to Glisson's capsule without penetration 4) several satellite nodules 5) resection margin: free of tumor <p>2. Remaining liver: nonspecific reactive hepatitis with hepatocellular cholestasis along the acinar zone 3</p> <p>3. Gallbladder, cholecystectomy: marked autolysis without carcinoma</p>	G2	T3N0M1 (IV)
40	G	7, 8	f	74	cholangio ca.	<p>1. Liver, lobectomy, right: Cholangiocarcinoma, hilar, involving right hepatic duct, part of left hepatic duct and common bile duct with</p> <ol style="list-style-type: none"> 1) occasional venous invasion 2) occasional perineural invasion <p>2. Remaining liver: multifocal infarction with portal fibrosis, bile duct proliferation and cholestasis</p> <ol style="list-style-type: none"> 1) resection margin, CBD, liver: free of tumor 2) resection margin, left hepatic duct: extension of tumor 3) regional lymph nodes, N12 (0/15), N12h (0/3), N12 (0/4), N16 (0/2) : (0/24) : free of tumor <p>3. Gallbladder, cholecystectomy: chronic nonspecific inflammation without evidence of tumor</p>	G2	T3N1M1 (IV)

A205: Liver cancer tissues - cholangiocarcinoma

No.	Coordinate		Sex	Age	Key Word	Histological Diagnosis	Grade	TNM Stage
41	G	9, 10	f	64	cholangio ca.	<p>1. Liver, left, lobectomy: Intraductal papillary cholangiocarcinoma, 1) involving left hepatic duct, bile ducts of inferior and superior segment and its branches</p> <p>2. Remaining liver: parenchymal atrophy fatty change, macro and microvesicular (1+) with portal fibrosis and chronic inflammation 1) resection margin: free of tumor</p> <p>3. Gallbladder: chronic nonspecific inflammation</p>	papillary cholangio ca.	T1N0M1 (IV)
42	G	11, 12	f	63	cholangio ca.	<p>1. Liver, segment viii, segmentectomy: Combined hepatocellular-cholangiocarcinoma, transitional type with 1) size: 3x2.5 cm in two dimension 2) expanding growth 3) marked sclerotic background 4) no vascular invasion 5) chronic hepatitis, b viral, with mild inflammatory activity (grade II) and macronodular cirrhosis (stage IV)</p> <p>2. Gallbladder, cholecystectomy: chronic nonspecific inflammation</p>	combined hepatocellular - cholangio ca.	T1N0M0 (I)
43	H	1, 2	f	71	cholangio ca.	<p>1. Liver, right, lobectomy: Cholangiocarcinoma with 1) arising from right hepatic duct 2) extensive perineural invasion 3) desmoplasia 4) portal vein: extension of tumor 5) resection margin, right hepatic duct: focal epithelial atypia with artifact 6) resection margin, liver: free of tumor 7) lymph nodes, No.8 (0/2): free of tumor</p> <p>2. Gallbladder: chronic nonspecific inflammation</p>	G2	T3N1M1 (IV)

A205: Liver cancer tissues - cholangiocarcinoma

No.	Coordinate		Sex	Age	Key Word	Histological Diagnosis	Grade	TNM Stage
44	H	3, 4	f	74	cholangio ca.	<p>1. Liver, right risegmentectomy with cholangiojejunostomy: Cholangiocarcinoma, moderately differentiated, hilar (klatskin tumor) with</p> <ol style="list-style-type: none"> 1) involvement of right hepatic duct including branches, part of left hepatic duct, common hepatic duct and cystic duct 2) frequent perineural and neural invasion 3) occasional vascular invasion <p>2. Remaining liver: Bile duct dilatation and periductal fibrosis</p> <p>3. Caudate lobe: free of tumor</p> <ol style="list-style-type: none"> 1) multifocal infarction <p>4. Gallbladder:</p> <ol style="list-style-type: none"> 1) tumor extension at the cystic duct and perimuscular soft tissue 2) multifocal ulceration with acute and chronic inflammation, granulation tissue formation and fibrosis 3) resection margin, common hepatic duct and left hepatic duct: extension of tumor 4) lymph node, regional: Hilar (0/1), LN8 (0/1), LN9 (0/3), LN12 (0/3) : (0/8): free of tumor <p>5. Soft tissue, labelled as "hepatic artery": extension of tumor</p>	G2	T2N0M1 (IV)
45	H	5, 6	f	62	cholangio ca.	<p>1. Liver, right lobe, lobectomy: Cholangiocarcinoma, moderately differentiated, peripheral type with</p> <ol style="list-style-type: none"> 1) size: 6 cm in the greast diameter 2) dense stromal fibrosis and marked necrosis 3) invasion to capsule 4) lymphovascular and perineural invasion 5) very close to hepatic resection margin (safety margin: about 1 mm) 6) reactive hepatitis <p>2. Gallbladder, cholecystectomy: free from tumor extension</p>	G2	T2NXM1 (IV)

A205: Liver cancer tissues - cholangiocarcinoma

No.	Coordinate	Sex	Age	Key Word	Histological Diagnosis	Grade	TNM Stage
46	H 7, 8	f	65	cholangio ca.	<p>1.Liver, right lobe, lobectomy: Cholangiocarcinoma, moderately differentiated, peripheral type 1) size: 11.5x9.5x7.0 cm 2) expanding growth and extensive necrosis 3) penetration of hepatic capsule and invasion to soft tissue adjacent to diaphragm 4) vascular invasion (but not portal vein) 5) intrahepatic metastasis 6) intact intrahepatic resection margin and diaphragm 7) nonneoplastic liver showing reactive hepatitis</p> <p>2.Gallbladder, cholecystectomy: free from tumor extension</p>	G2	T4NXM1 (IV)
47	H 9	f	57	bile duct	Non-neoplastic		
48	H 10	f	67	bile duct	Non-neoplastic		
49	H 11	m	57	bile duct	Non-neoplastic		
50	H 12	m	64	bile duct	Non-neoplastic		