

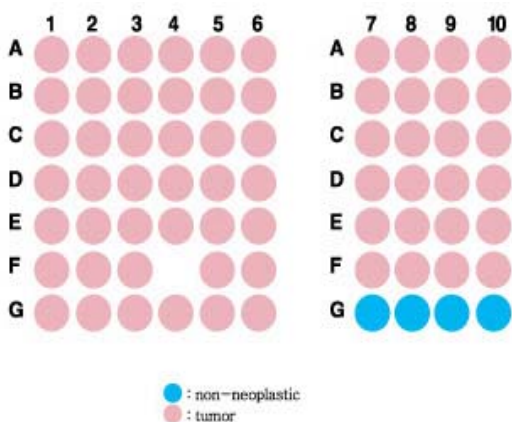
Specifications:

- No. of cases: 33
- Tissue type: Thyroid cancer tissues
- No. of spots: 2 spots from each cancer case (66 spots)
4 non-neoplastic spots (4 spots)
- Total spots: 70
- Corresponding normal tissues with cancers: Yes
- Diameter: 1.0 mm

Documents:

- Product specification: layout, summary of tissue spots
- H&E stained images
- Detailed pathological information

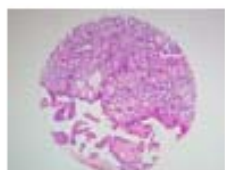Layout:



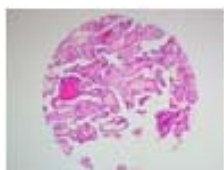Summary of tissue spots

No.	Coordinate	Sex	Age	Key Word	Surgery	TNM Stage	
1	A	1, 2	f	49	thyroid gland: papillary carcinoma	dissection	T3N1aM0
2		3, 4	f	48	thyroid gland: papillary carcinoma	thyroidectomy	T3NxM0
3		5, 6	f	28	thyroid gland: papillary carcinoma	total thyroidectomy	T4N1bM0
4		7, 8	m	49	thyroid gland: medullary carcinoma	lobectomy	T3N1M0
5		9, 10	f	28	thyroid gland: medullary carcinoma	lobectomy	T1N1M0
6	B	1, 2	f	57	thyroid gland: papillary carcinoma	thyroidectomy	T1N0M0
7		3, 4	f	39	thyroid gland: papillary carcinoma	total thyroidectomy	T3N1Mx
8		5, 6	f	30	thyroid gland: papillary carcinoma	total thyroidectomy	T3N1M0
9		7, 8	f	46	thyroid gland: medullary carcinoma	thyroidectomy	T3N1M0
10		9, 10	f	35	thyroid gland: medullary carcinoma	frozen biopsy	T1NxM0
11	C	1, 2	f	46	thyroid gland: papillary carcinoma lymph node: metastatic carcinoma	total thyroidectomy	T3N1Mx
12		3, 4	f	60	thyroid gland: papillary carcinoma	total thyroidectomy	T3N0M0
13		5, 6	f	27	thyroid gland: papillary carcinoma	total thyroidectomy	T3N1M0
14		7, 8	m	39	thyroid gland: medullary carcinoma	thyroidectomy and frozen biopsy	
15		9, 10	f	30	thyroid gland: adenomatous hyperplasia	lobectomy	
16	D	1, 2	f	30	thyroid gland: papillary carcinoma lymph node: metastatic papillary carcinoma	total thyroidectomy	T2N1bM0
17		3, 4	m	36	thyroid gland: papillary carcinoma	lobectomy	T3NxMx
18		5, 6	f	28	thyroid gland: follicular carcinoma	lobectomy	T2N0Mx
19		7, 8	f	64	thyroid gland: adenomatous hyperplasia	lobectomy	
20		9, 10	f	38	thyroid gland: adenomatous hyperplasia	lobectomy	
21	E	1, 2	f	60	thyroid gland: follicular carcinoma	thyroidectomy and frozen biopsy	T3NxM0
22		3, 4	f	47	thyroid gland: follicular carcinoma	thyroidectomy	T1NxM0
23		5, 6	f	47	thyroid gland: follicular carcinoma	thyroidectomy	T2NxM0
24		7, 8	f	36	thyroid gland: adenomatous hyperplasia	lobectomy	
25		9, 10	f	43	thyroid gland: adenomatous hyperplasia	lobectomy	
26	F	1, 2	f	28	thyroid gland: follicular carcinoma	thyroidectomy	T1N0M0
27		3, 4	f	41	thyroid gland: anaplastic carcinoma	lobectomy	T4bNxMx
28		5, 6	m	48	thyroid gland: anaplastic carcinoma	thyroidectomy	T4bN1M0
29		7, 8	f	30	thyroid gland: follicular adenoma	lobectomy	
30		9, 10	f	69	thyroid gland: follicular adenoma	lobectomy	
31	G	1, 2	f	29	thyroid gland: follicular adenoma	lobectomy	
32		3, 4	f	43	thyroid gland: follicular adenoma	lobectomy	
33		5, 6	f	26	thyroid gland: follicular adenoma	lobectomy	
34		7	f	49	non-neoplastic, from A1, 2		
35		8	f	39	non-neoplastic, from B 3, 4		
36		9	f	48	non-neoplastic, from A3, 4		
37		10	f	57	non-neoplastic, from B1, 2		

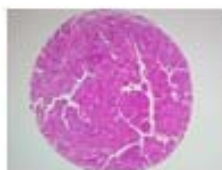
QC sheet_LOT#122120308271
Haematoxylin and Eosin staining



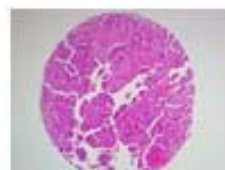A1



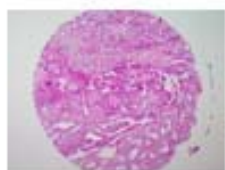A2



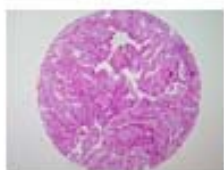A3



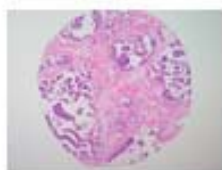A4



A5



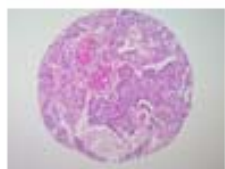
A6



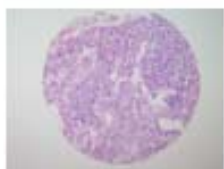
A7



A8



A9



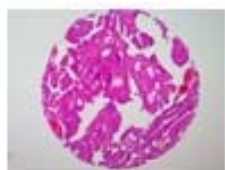
A10



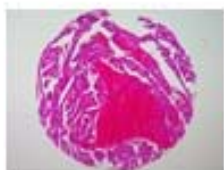B1



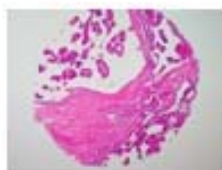B2



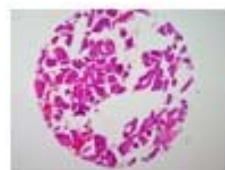B3



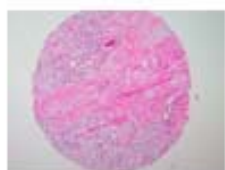B4



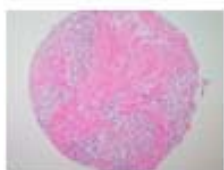B5



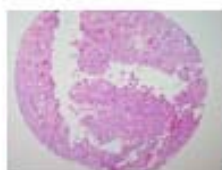B6



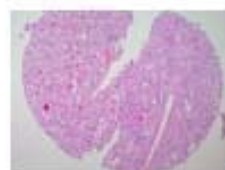
B7



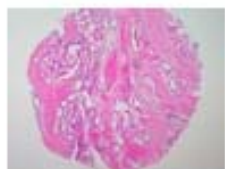B8



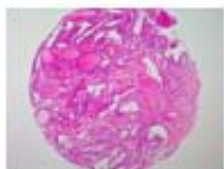B9



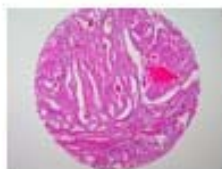B10



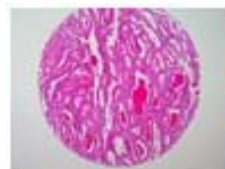C1



C2

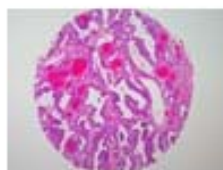

C3

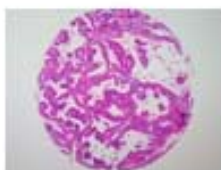

C4

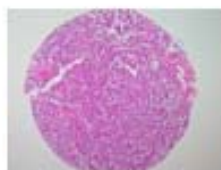QC sheet_LOT#122120308271
Haematoxylin and Eosin staining



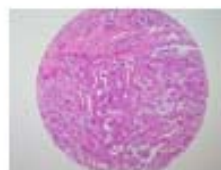C5



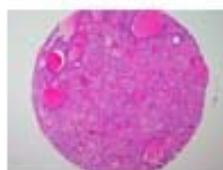
C6



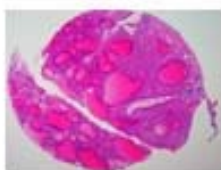
C7



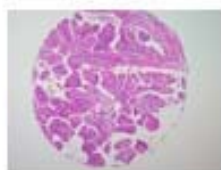
C8



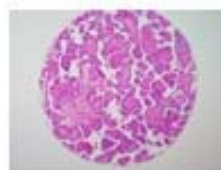
C9



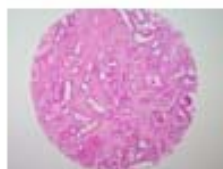C10



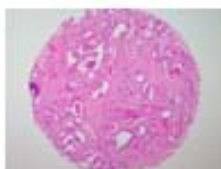D1



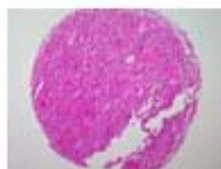D2



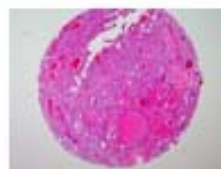D3



D4



D5



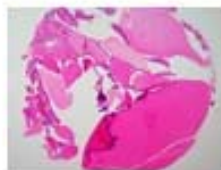D6



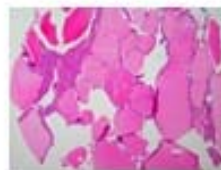D7



D8



D9



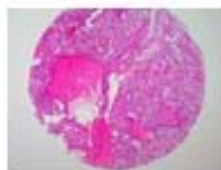
D10



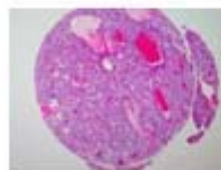
E1



E2



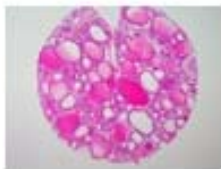E3



E4



E5



E6

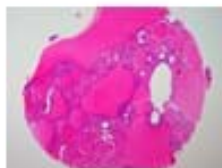

E7

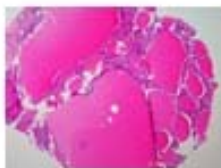

E8

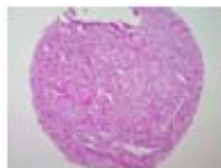
QC sheet_LOT#122120308271
Haematoxylin and Eosin staining



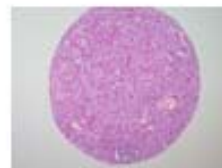
E9



E10



F1



F2



F3



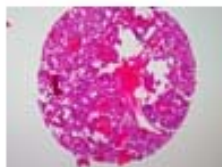F4



F5



F6



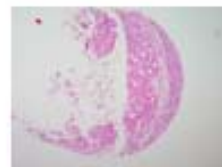F7



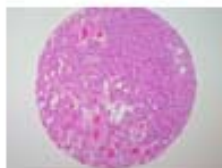F8



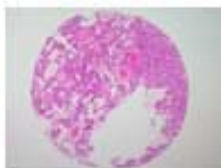F9



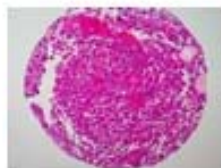
F10



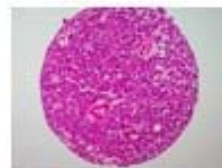G1



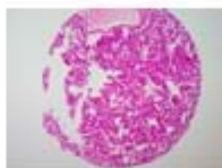G2



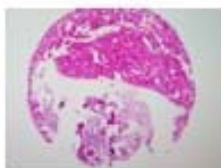G3



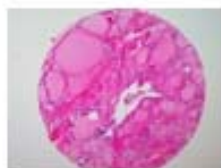G4



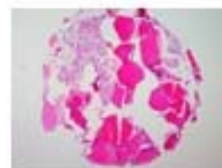
G5



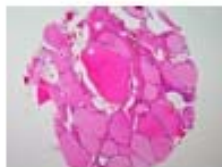G6



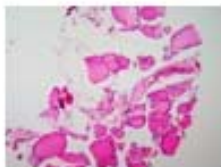
G7



G8



G9



G10

A210: Thyroid cancer tissues

No.	Coordinate		Sex	Age	Key Word	Histological Diagnosis	Surgery	TNM Stage
1	A	1, 2	f	49	thyroid gland: papillary carcinoma	Thyroid gland total thyroidectomy with dissection: 1. Papillary carcinoma involving both lobes (intrathyroidal metastasis) and penetrating capsule with extension to the perithyroidal soft tissue 2. Resection margin: free of tumor 3. Lymph nodes, No.3,4 (0/14), No.6,7 (1/4): (1/18): metastatic papillary carcinoma in 1 out of 18 lymph nodes 4. Soft tissue, submitted as No.6,7 lymph node: presence of papillary carcinoma	dissection	T3N1aM0
2	A	3, 4	f	48	thyroid gland: papillary carcinoma	Thyroid, left, thyroidectomy: 1. Papillary carcinoma with extrathyroidal extension to the perithyroidal	thyroidectomy	T3NxM0
3	A	5, 6	f	28	thyroid gland: papillary carcinoma	Thyroid gland, both, total thyroidectomy: 1. Papillary carcinoma in the right lobe with extension to the perithyroidal soft tissue. 2. Lymph nodes, No.1 (2/2), No.2 (2/2), right recurrent laryngeal nerve (10/15) and regional (4/4) : (18/23): tumor metastasis to 18 out of 23 lymph nodes with perinodal soft tissue extension	total thyroidectomy	T4N1bM0
4	A	7, 8	m	49	thyroid gland: medullary carcinoma	Thyroid gland, lobectomy: 1. Medullary carcinoma with extension beyond the capsule	lobectomy	T3N1M0
5	A	9, 10	f	28	thyroid gland: medullary carcinoma	Thyroid gland, left, lobectomy: 1. Medullary carcinoma	lobectomy	T1N1M0
6	B	1, 2	f	57	thyroid gland: papillary carcinoma	Thyroid gland, left, thyroidectomy: 1. Three separate foci of papillary carcinoma 2. Suture granuloma/abscess 3. Lymph nodes, neck, dissection: benign reactive lymph node with sinus histiocyte hyperplasia and non-caseating granulomatous lesions of regional lymph nodes (0/19)	thyroidectomy	T1N0M0

A210: Thyroid cancer tissues

No.	Coordinate		Sex	Age	Key Word	Histological Diagnosis	Surgery	TNM Stage
7	B	3, 4	f	39	thyroid gland: papillary carcinoma	Thyroid gland, total thyroidectomy: 1. Papillary carcinoma with 1) extension to the extrathyroidal soft tissue and skeletal muscle 2) lymphovascular invasion 2. Lymph nodes (11/13): metastasis in 11 out 13 nodes	total thyroidectomy	T3N1Mx
8	B	5, 6	f	30	thyroid gland: papillary carcinoma	Thyroid gland, total thyroidectomy: 1. Papillary carcinoma, in both lobes with 1) size: 4.3 cm in the greatest diameter 2) penetration of capsule and extension to surrounding fibroadipose tissue 3) lymphovascular invasion 4) involvement at resection margin 2. Lymph node metastasis to 10 out of 17 to regional lymph nodes	total thyroidectomy	T3N1M0
9	B	7, 8	f	46	thyroid gland: medullary carcinoma	Thyroid gland, thyroidectomy: 1. Medullary carcinoma, focally extending beyond the capsule	thyroidectomy	T3N1M0
10	B	9, 10	f	35	thyroid gland: medullary carcinoma	Thyroid, thyroidectomy, frozen biopsy: 1. Medullary carcinoma, intrathyroid with multifocal C-cell hyperplasia in adjacent thyroid parenchyme, in associated with MEN IIa	frozen biopsy	T1NxM0
11	C	1, 2	f	46	thyroid gland : papillary carcinoma lymph node : metastatic carcinoma	Thyroid gland, total thyroidectomy: 1. Papillary carcinoma with extension beyond thyroid capsule to the perithyroidal soft tissue 2. Lymph nodes (4/8), neck, left, excision: metastatic carcinoma in 4 out of 8 nodes	total thyroidectomy	T3N1Mx
12	C	3, 4	f	60	thyroid gland : papillary carcinoma	Thyroid gland, total thyroidectomy: 1. Papillary carcinoma with extension to the perithyroid fibrous tissue of right lobe 2. Lymph nodes, neck, right, dissection: free of tumor (0/11)	total thyroidectomy	T3N0M0

A210: Thyroid cancer tissues

No.	Coordinate		Sex	Age	Key Word	Histological Diagnosis	Surgery	TNM Stage
13	C	5, 6	f	27	thyroid gland: papillary carcinoma	Thyroid, total, thyroidectomy: 1. Papillary carcinoma, in both lobe with 1) involvement at more than 2/3 of entire parenchyma 2) extensive invasion into surrounding fibroadipose tissue, and direct extension to some lymph nodes (4/4) 3) lymphovascular invasion 4) metastasis to out 11 of 37 lymph nodes (right level III (0/1), level II and IV (4/16), right level VI (0/4), and perithyroidal (7/16))	total thyroidectomy	T3N1M0
14	C	7, 8	m	39	thyroid gland: medullary carcinoma	Thyroid gland, thyroidectomy and frozen biopsy: 1. Medullary carcinoma of thyroid origin (size:2 cm in maximal diameter)	thyroidectomy and frozen biopsy	
15	C	9, 10	f	30	thyroid gland: adenomatous hyperplasia	Thyroid gland, right, lobectomy: 1. Adenomatous hyperplasia	lobectomy	
16	D	1, 2	f	30	thyroid gland: papillary carcinoma lymph node: metastatic papillary carcinoma	Thyroid, right, total thyroidectomy: 1. Papillary carcinoma (size: 1 cm) with micrometastatic papillary carcinoma involving one regional lymph nodes (1/2) 2. Lymph nodes, dissection: metastatic papillary carcinoma in 2 out of 21 lymph nodes 3. Lymph nodes, dissection: metastatic papillary carcinoma in 2 out of 10 lymph nodes	total thyroidectomy	T2N1bM0
17	D	3, 4	m	36	thyroid gland: papillary carcinoma	Thyroid gland, right, lobectomy: 1. Papillary carcinoma (size: 0.8 cm) with extension to the perithyroidal fibrofatty tissue	lobectomy	T3NxMx
18	D	5, 6	f	28	thyroid gland: follicular carcinoma	Thyroid, right, lobectomy: 1. Follicular carcinoma	lobectomy	T2N0Mx
19	D	7, 8	f	64	thyroid gland: adenomatous hyperplasia	Thyroid gland, left, lobectomy: 1. Adenomatous hyperplasia	lobectomy	

A210: Thyroid cancer tissues

No.	Coordinate		Sex	Age	Key Word	Histological Diagnosis	Surgery	TNM Stage
20	D	9, 10	f	38	thyroid gland: adenomatous hyperplasia	Thyroid gland, left, lobectomy: 1. Adenomatous hyperplasia	lobectomy	
21	E	1, 2	f	60	thyroid gland: follicular carcinoma	Thyroid, thyroidectomy and frozen biopsy: 1. Encapsulated follicular carcinoma with capsular and vascular invasion 2. Microscopic papillary carcinoma, separated from main tumor	thyroidectomy and frozen biopsy	T3NxM0
22	E	3, 4	f	47	thyroid gland: follicular carcinoma	Thyroid, thyroidectomy: 1. Encapsulated follicular carcinoma with capsular invasion, and angioinvasion, intrathyroidal	thyroidectomy	T1NxM0
23	E	5, 6	f	47	thyroid gland: follicular carcinoma	Thyroid gland, thyroidectomy: 1. Smaller mass: follicular carcinoma, intrathyroidal 2. Larger mass: adenomatous hyperplasia	thyroidectomy	T2NxM0
24	E	7, 8	f	36	thyroid gland: adenomatous hyperplasia	Thyroid gland, left, lobectomy: 1. Adenomatous hyperplasia	lobectomy	
25	E	9, 10	f	43	thyroid gland: adenomatous hyperplasia	Thyroid gland, right, lobectomy: 1. Adenomatous hyperplasia 2. Lymph nodes, regional (0/2): free of tumor	lobectomy	
26	F	1, 2	f	28	thyroid gland: follicular carcinoma	Thyroid gland, thyroidectomy: 1. Follicular carcinoma, confined to the thyroid gland	thyroidectomy	T1N0M0
27	F	3, 4	f	41	thyroid gland : anaplastic carcinoma	Thyroid gland, lobectomy: 1. Left lobe: 1) adenomatous hyperplasia 2) papillary carcinoma (3 mm) 2. tumor mass: Anaplastic carcinoma, squamoid pattern with involvement of perithyroidal soft tissue	lobectomy	T4bNxMx

A210: Thyroid cancer tissues

No.	Coordinate		Sex	Age	Key Word	Histological Diagnosis	Surgery	TNM Stage
28	F	5, 6	m	48	thyroid gland: anaplastic carcinoma	Thyroid gland, left, thyroidectomy: 1. Anaplastic carcinoma composing squamous cell carcinoma and papillary carcinoma 2. Presence of parathyroid gland Thyroid gland, tracheoesophageal groove: 1. Anaplastic carcinoma with perineural invasion 2. Cervical lymph node, right, level II (0/19), level III (0/6), level IV (2/8): metastatic papillary carcinoma in 2 out of 33 nodes	thyroidectomy	T4bN1M0
29	F	7, 8	f	30	thyroid gland: follicular adenoma	Thyroid gland, left, lobectomy: 1. Follicular adenoma	lobectomy	
30	F	9, 10	f	69	thyroid gland: follicular adenoma	Thyroid gland, right, lobectomy: 1. Follicular adenoma	lobectomy	
31	G	1, 2	f	29	thyroid gland: follicular adenoma	Thyroid gland, left, lobectomy: 1. Follicular adenoma	lobectomy	
32	G	3, 4	f	43	thyroid gland: follicular adenoma	Thyroid gland, left, lobectomy: 1. Follicular adenoma 2. Adenomatous hyperplasia	lobectomy	
33	G	5, 6	f	26	thyroid gland: follicular adenoma	Thyroid gland, right, lobectomy: 1. Follicular adenoma	lobectomy	
34	G	7	f	49	non-neoplastic	Non-neoplastic, from A1, 2		
35	G	8	f	39	non-neoplastic	Non-neoplastic, from B 3, 4		
36	G	9	f	48	non-neoplastic	Non-neoplastic, from A3, 4		
37	G	10	f	57	non-neoplastic	Non-neoplastic, from B1, 2		