

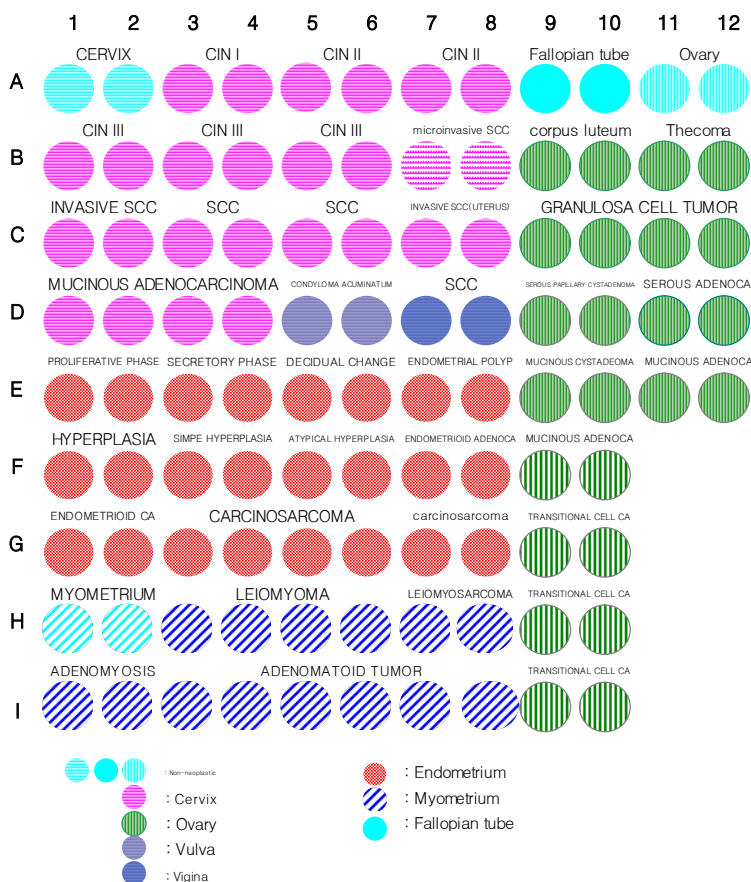
Specifications:

- No. of cases: 50
- Tissue type: Uterus cancer tissues
- No. of spots: 2 spots from each cancer case (100 spots)
- Total spots: 100
- Corresponding normal tissues with cancers: No
- Diameter: 1.0 mm

Documents:

- Product specification: layout, summary of tissue spots
- H&E stained images
- Detailed pathological information

Layout:



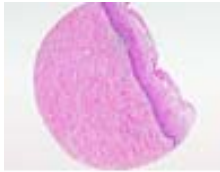
Summary of tissue spots

No.	Coordinat	Sex	Age	Key Word	TNM Stage	
1	A	1,2	f	42	cervix: non-neoplastic	
2		3,4	f	50	cervix: CIN I	
3		5,6	f	84	cercix: CIN II	
4		7,8	f	53	cervix: CIN II	
5		9,10	f	36	fallopian tube: non-neoplastic	
6		11,12	f	49	ovary: non-neoplastic	
7	B	1,2	f	45	cervix: CIN III	
8		3,4	f	42	cervix: CIN III	
9		5,6	f	38	cervix: CIN III	T1a1N0M0 (I A1)
10		7,8	f	68	cervix: microinvasive squamous cell carcinoma	T1a1N0M0 (I A1)
11		9,10	f	48	ovary: corpus luteum	
12		11,12	f	53	ovary: thecoma	
13	C	1,2	f	37	cervix: invasive squamous cell carcinoma	T1b1N0M0 (I B1)
14		3,4	f	53	cervix: squamous cell carcinoma	T1b1N0M0 (I B1)
15		5,6	f	36	cervix: squamous cell carcinoma	T1bN1M0 (III B)
16		7,8	f	33	uterus: invasive squamous cell carcinoma	
17		9,10	f	79	ovary: granulosa cell tumor	
18		11,12	f	38	ovary: granulosa cell tumor	
19	D	1,2	f	44	cervix: mucinous adenocarcinoma	T1b1N0M0 (I B1)
20		3,4	f	42	cervix: mucinous adenocarcinoma	T1b1N0M0 (I B1)
21		5,6	f	63	vulva: condyloma acuminatum	
22		7,8	f	44	vagina: squamous cell carcinoma	
23		9,10	f	25	ovary: serous papillary cystadenoma	
24		11,12	f	41	ovary: serous adenocarcinoma	T3cN0M0 (III C)
25	E	1,2	f	38	endometrium: proliferative phase	
26		3,4	f	41	endometrium: secretory phase	
27		5,6	f	27	endometrium: decidual change	
28		7,8	f	49	endometrium: endometrial polyp	
29		9,10	f	67	ovary: mucinous cystadenoma	
30		11,12	f	68	ovary: mucinous adenocarcinoma	

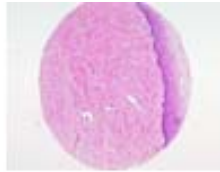Summary of tissue spots

No.	Coordinat	Sex	Age	Key Word	TNM Stage
31	1,2	f	49	endometrium hyperplasia	
32	3,4	f	46	endometrium: simple hyperplasia	
33	5,6	f	46	endometrium: atypical hyperplasia	
34	7,8	f	54	endometrium: endometrioid adenocarcinoma	T1bN0M0 (I B)
35	9,10	f	57	ovary: mucinous adenocarcinoma	T1aN0M0 (I A)
36	1,2	f	69	endometrium: endometrioid carcinoma	T1bN0M0 (I B)
37	3,4	f	50	endometrium: endometrioid adenocarcinoma	T3N1M0 (III C)
38	5,6	f	56	endometrium: endometrioid adenocarcinoma	T1cN0M1 (IVB)
39	7,8	f	71	endometrium: carcinosarcoma	
40	9,10	f	47	ovary: endometrioid adenocarcinoma	T1bN0M0 (I B)
41	1,2		49	myometrium: non neoplastic	
42	3,4	f	41	myometrium: leiomyoma	
43	5,6	f	49	myometrium: leiomyoma	
44	7,8	f	37	myometrium: leiomyosarcoma	
45	9,10	f	41	ovary: transitional cell carcinoma	T3bNxM1 (IV)
46	1,2	f	47	myometrium: adenomyosis	
47	3,4	f	38	myometrium: adenomatoid tumor	
48	5,6	f	43	myometrium: adenomatoid tumor	
49	7,8	f	47	myometrium: adenomatoid tumor	
50	9,10	f	57	ovary: transitional cell carcinoma	T3bN1M1 (IV)

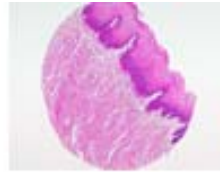
QC sheet_LOT#122120406201
Hematoxylin and Eosin staining



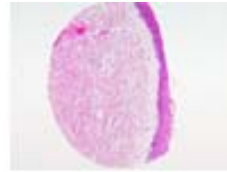
A1



A2



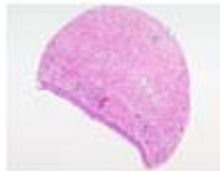A3



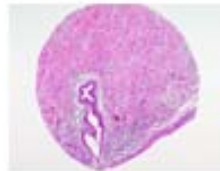
A4



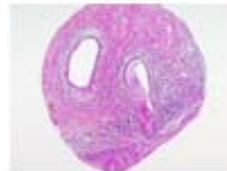
A5



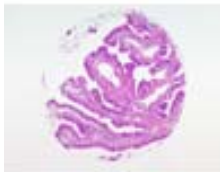
A6



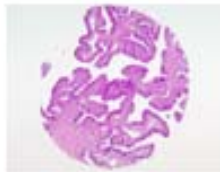
A7



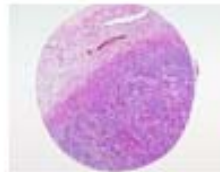A8



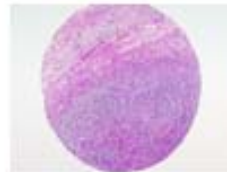A9



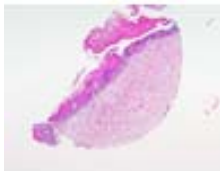
A10



A11



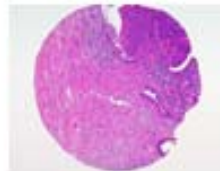
A12



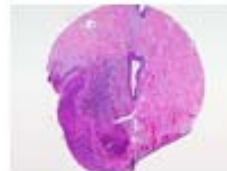
B1



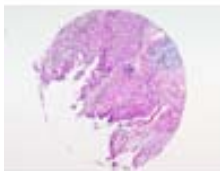
B2



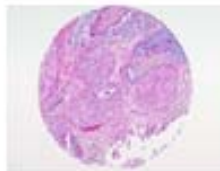
B3



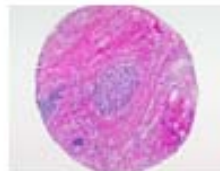B4



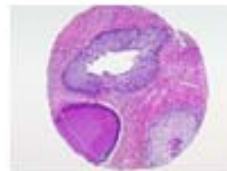
B5



B6



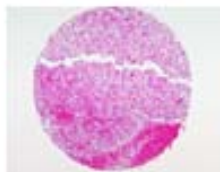B7



B8



B9



B10

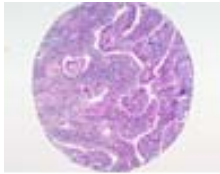


B11

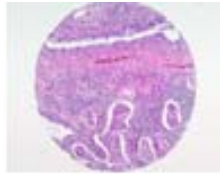


B12

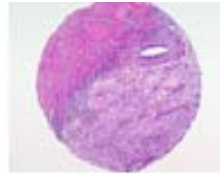
QC sheet_LOT#122120406201
Hematoxylin and Eosin staining



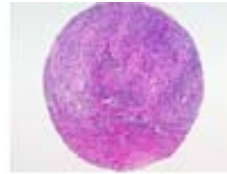
C1



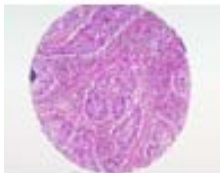
C2



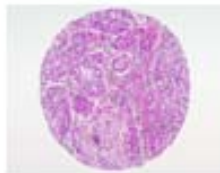
C3



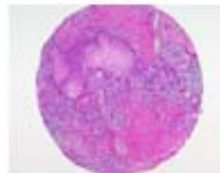C4



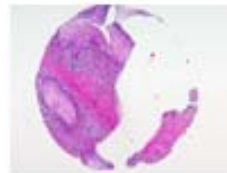
C5



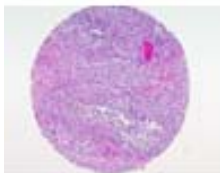C6



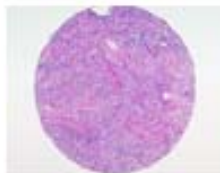C7



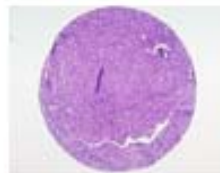C8



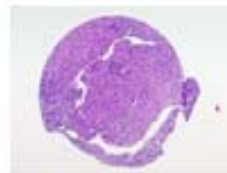
C9



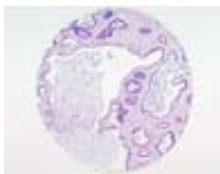C10



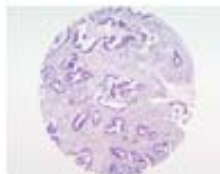C11



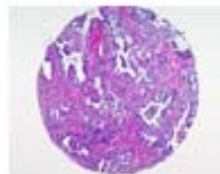
C12



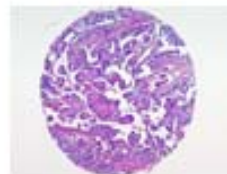D1



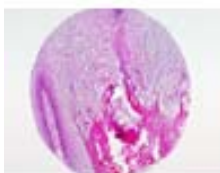D2



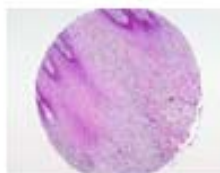D3



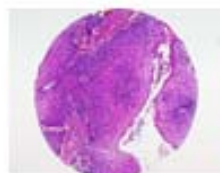
D4



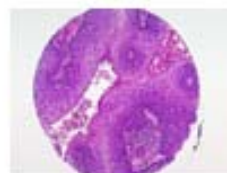
D5



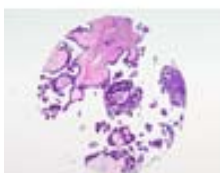D6



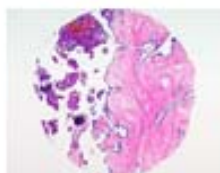
D7



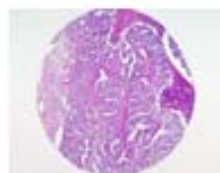
D8



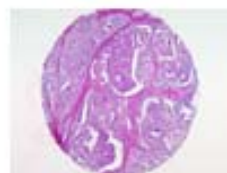D9



D10

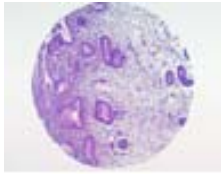


D11

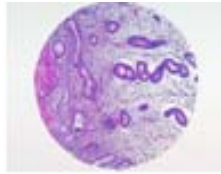


D12

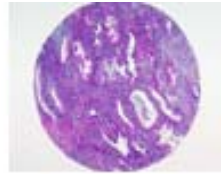QC sheet_LOT#122120406201
Hematoxylin and Eosin staining



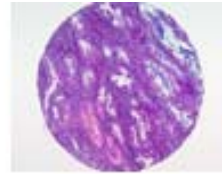E1



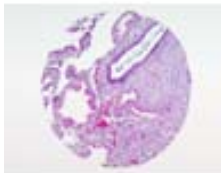
E2



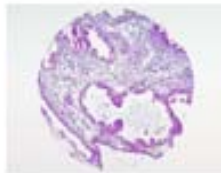
E3



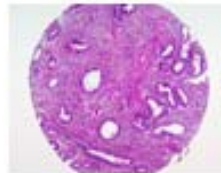
E4



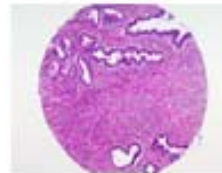
E5



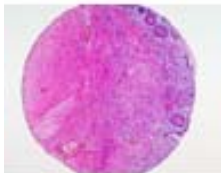E6



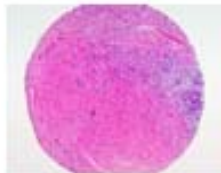E7



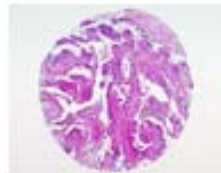E8



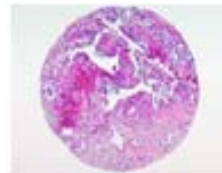
E9



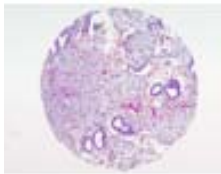
E10



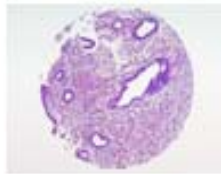
E11



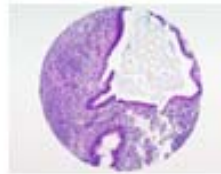
E12



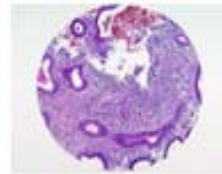
F1



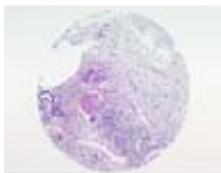
F2



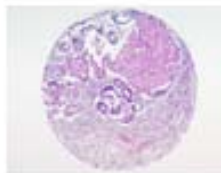
F3



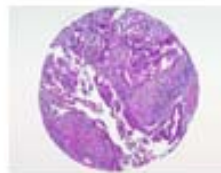
F4



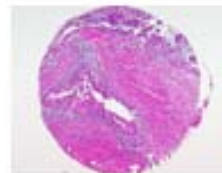F5



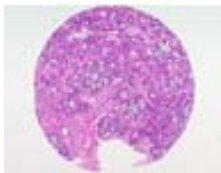F6



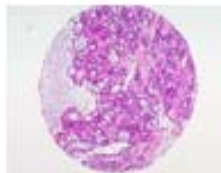
F7



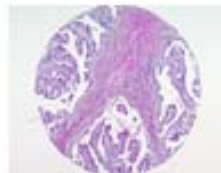
F8



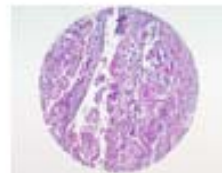
F9



F10

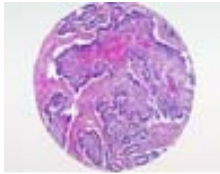


G1

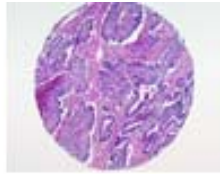


G2

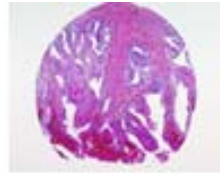
QC sheet_LOT#122120406201
Hematoxylin and Eosin staining



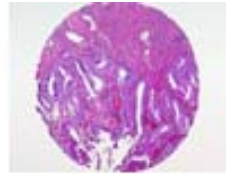G3



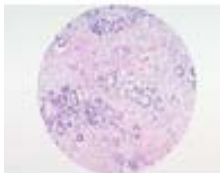
G4



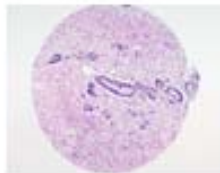
G5



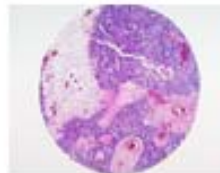
G6



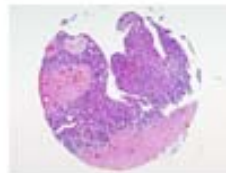
G7



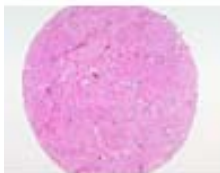G8



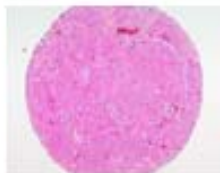G9



G10



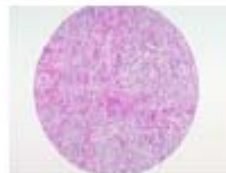H1



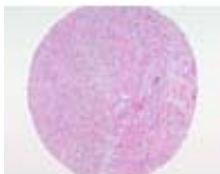H2



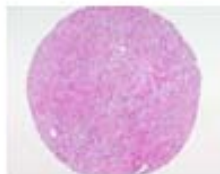H3



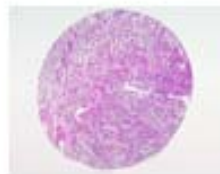H4



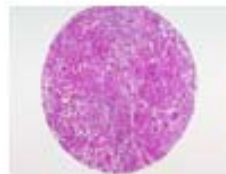H5



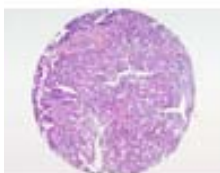
H6



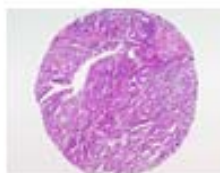H7



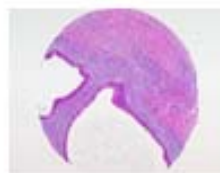H8



H9



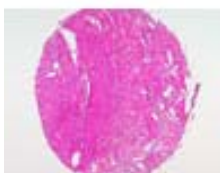H10



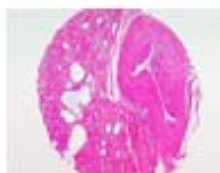I1



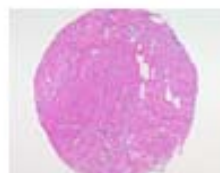I2



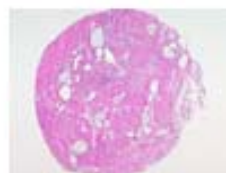I3



I4

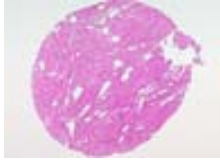

I5

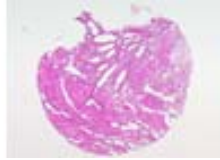


I6

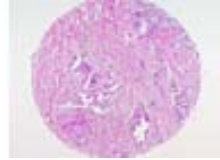
QC sheet_LOT#122120406201
Hematoxylin and Eosin staining



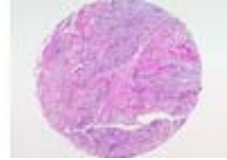
17



18



19



110

A212: Uterus cancer tissues

No.	Coordinat		Sex	Age	Key word	Histological Diagnosis	TNM Stage
6	A	11,12	f	49	ovary: non-neoplastic	Uterus, right adnexa, total abdominal hysterectomy with right salpingoophorectomy: 1) cervix: chronic nonspecific inflammation 2) endometrium: proliferative phase 3) myometrium: adenomyosis 4) ovary, right: no pathological diagnosis 5) fallopian tube, right: no pathological diagnosis	
7	B	1,2	f	45	cervix: CIN III	Uterus, total abdominal hysterectomy: 1) cervix: - postbiopsy state with residual adenocarcinoma in situ, well differentiated - high grade squamous intraepithelial lesion(CIN III) 2) endometrium: proliferative phase 3) myometrium : - leiomyomas, intramural - adenomyosis 4) parametriums, both: free of tumor	
8	B	3,4	f	42	cervix: CIN III	Uterus, total abdominal hysterectomy: 1) cervix: high grade squamous intraepithelial lesion (carcinoma in situ) with intact exocervical resection margin 2) endometrium: secretory phase 3) myometrium: leiomyoma, intramural	
9	B	5,6	f	38	cervix: CIN III	Uterus, total abdominal hysterectomy: 1) cervix: microinvasive squamous cell carcinoma (depth of invasion: <1 mm) with clean surgical margin 2) endometrium: proliferative phase 3) myometrium: adenomyosis	T1a1N0M0 (I A1)

A212: Uterus cancer tissues

No.	Coordinat	Sex	Age	Key word	Histological Diagnosis	TNM Stage
10	B 7,8	f	68	cervix: microinvasive squamous cell carcinoma	Uterus with both adnexae, total abdominal hysterectomy with bilateral salpingoophorectomy: 1) cervix: microinvasive squamous cell carcinoma (depth of invasion: 1 mm) 2) endometrium: atrophy 3) myometrium: no pathological diagnosis 4) ovaries, both: free of tumor 5) fallopian tubes, both: free of tumor 6) parametrium, both: free of tumor 7) resection margin of the cervix: free of tumor	T1a1N0M0 (I A1)
11	B 9,10	f	48	ovary: corpus luteum	Uterus with both adnexae, total abdominal hysterectomy with bilateral salpingoophorectomy: 1) cervix: chronic nonspecific inflammation 2) endometrium: secretory phase 3) myometrium: leiomyoma, submucosal, polypoid 4) ovary, right: corpus luteum 5) ovary, left : no pathological diagnosis 6) fallopian tubes, bilateral: no pathological diagnosis	
12	B 11,12	f	53	ovary: thecoma	Ovary, oophorectomy: thecofibroma with minor sex cord element	

A212: Uterus cancer tissues

No.	Coordinat	Sex	Age	Key word	Histological Diagnosis	TNM Stage	
13	C	1,2	f	37	cervix: invasive squamous cell carcinoma	<p>Uterus, total abdominal hysterectomy:</p> <p>1) cervix: invasive squamous cell carcinoma, large cell, nonkeratinizing type, at area between 3-6 o'clock directions</p> <ul style="list-style-type: none"> - size: 2.5x2x0.8 cm - depth of invasion: 8 mm - expanding growth - no vascular invasion - intact resection margins of vaginal cuff <p>2) endometrium:</p> <ul style="list-style-type: none"> - secretory phase without tumor extension - adenomyosis <p>3) parametrium, bilateral: free from tumor extension</p> <p>4) regional lymph nodes, right (0/6) and left (0/5) and pelvic, separately submitted: free from tumor extension</p>	T1b1N0M0 (I B1)
14	C	3,4	f	53	cervix: squamous cell carcinoma	<p>Uterus including both adnexa, total abdominal hysterectomy with bilateral salpingoophorectomy:</p> <p>1) cervix: invasive squamous cell carcinoma, large cell, non-keratinizing type without lymphatic invasion (depth of invasion: 8/15 mm)</p> <p>2) endometrium: atrophy</p> <p>3) myometrium: adenomyosis</p> <p>4) ovaries, bilateral: no pathological diagnosis</p> <p>5) fallopian tubes, bilateral: no pathological diagnosis</p> <p>6) parametriums, bilateral: free of tumor</p> <p>7) vaginal cuff: free of tumor</p> <p>8) lymph nodes, left, parametrial (0/2), right pelvic (0/4) and left pelvic (0/3): free of tumor metastasis in all 9 nodes</p>	T1b1N0M0 (I B1)

A212: Uterus cancer tissues

No.	Coordinat	Sex	Age	Key word	Histological Diagnosis	TNM Stage	
15	C	5,6	f	36	cervix: squamous cell carcinoma	Uterus with adnexa, left and lymph node, pelvic, radical abdominal hysterectomy with left salpingoophorectomy and dissection: 1) cervix: invasive adenosquamous cell carcinoma with focal lymphovascular permeation showing squamous cell carcinoma, large cell, non-keratinizing type (invasion depth: 1.2 cm), and mucinous adenocarcinoma, endocervical type, moderately differentiated 2) endometrium: secretory phase 3) myometrium: no pathological diagnosis 4) ovary, left: no pathological diagnosis 5) fallopian tube, left: no pathological diagnosis 6) parametria, bilateral: free of tumor 7) vaginal cuff: free of tumor 8) lymph nodes, right pelvic (0/14), left pelvic (2/7) and common iliac (0/3),(2/24): metastatic adenosquamous cell carcinoma in 2 out of 24 lymph nodes	T1bN1M0 (IIIB)
16	C	7,8	f	33	uterus: invasive squamous cell carcinoma	Uterus with lymph nodes, pelvic, radical abdominal hysterectomy with dissection: 1) cervix: invasive squamous cell carcinoma, large cell, keratinizing (invasion depth: 1.1cm) with focal lymphovascular permeation. 2) endometrium: proliferative phase 3) myometrium: adenomyosis 4) parametria, bilateral: free of tumor 5) vaginal cuff: free of tumor 6) lymph nodes, right pelvic (0/4), left pelvic (0/6), regional (0/2): (0/12): free of tumor	
17	C	9,10	f	79	ovary: granulosa cell tumor	Uterus with both adnexae, total abdominal hysterectomy with bilateral salpingoophorectomy: 1) cervix: chronic nonspecific inflammation 2) endometrium: simple hyperplasia without atypia 3) myometrium: no pathological diagnosis 4) ovary, right: granulosa cell tumor, poorly differentiated (mitotic index: 5/10 HPF) 5) ovary, left: endosalpingiosis 6) fallopian tube, both: no pathological diagnosis	

A212: Uterus cancer tissues

No.	Coordinat	Sex	Age	Key word	Histological Diagnosis	TNM Stage	
18	C	11,12	f	38	ovary: granulosa cell tumor	Ovary, left, oophorectomy: adult granulosa cell tumor, poorly differentiated (diffuse pattern), with mild atypia and increased mitotic figures including atypical mitosis (5/10HPF)	
19	D	1,2	f	44	cervix: mucinous adenocarcinoma	Uterus with right adnexa radical abdominal hysterectomy: 1) cervix: invasive mucinous adenocarcinoma, intestinal type (depth of invasion: 8 mm) 2) endometrium: post curettage status 3) myometrium: no pathological diagnosis 4) ovary: no pathological diagnosis 5) fallopian tube: no pathological diagnosis 6) parametrium, both: free of tumor 7) vaginal cuff: free of tumor Regional lymph node, pelvic node dissection right pelvic (0/4), left pelvic (0/7,(1/11)): free of tumor	T1b1N0M0 (I B1)
20	D	3,4	f	42	cervix: mucinous adenocarcinoma	Uterus with adnexa, left, radical abdominal hysterectomy with left salpingo-oophorectomy: 1) cervix: - mucinous adenocarcinoma, endocervical type, moderately differentiated with multifocal lymphovascular permeation (invasion depth: 5 mm) - microinvasive squamous cell carcinoma with extensive carcinoma in situ (invasion depth: 1.5 mm) 2) endometrium: secretory phase 3) myometrium: leiomyomas, multiple, intramural 4) ovary, left: no pathological diagnosis 5) fallopian tube, left: no pathological diagnosis 6) parametrium, bilateral: free of tumor 7) vaginal cuff: free of tumor 8) lymph nodes, pelvic (0/17): free of tumor	T1b1N0M0 (I B1)
21	D	5,6	f	63	vulva; condyloma acuminatum	Vulva, excisional biopsy: condyloma acuminatum, with focal erosion, completely excised	
22	D	7,8	f	44	vagina: squamous cell carcinoma	Vagina, biopsy: invasive squamous cell carcinoma, well differentiated	

A212: Uterus cancer tissues

No.	Coordinat	Sex	Age	Key word	Histological Diagnosis	TNM Stage
23	D 9,10	f	25	ovary: serous papillary cystadenoma	Ovary, right, oophorectomy: serous papillary cystadenoma, borderline malignancy (serous borderline tumor) with prominent micropapillary pattern	
24	D 11,12	f	41	ovary: serous adenocarcinoma	1. Uterus including both adnexae, total abdominal hysterectomy with bilateral salpingoophorectomy: 1) cervix: chronic nonspecific inflammation with squamous metaplasia 2) endometrium: proliferative phase 3) myometrium : serosal invasion by ovarian adenocarcinoma 4) ovaries, bilateral: serous papillary adenocarcinoma, grade 2, bilateral, with extension beyond ovarian capsule to the pelvic and abdominal peritoneum 5) fallopian tubes, bilateral: serosal and intraluminal tumor involvement 6) parametrium, bilateral: extension of the tumor 7) lymph nodes, right pelvic (0/1), left pelvic (0/3) and paraaortic (0/3): free of tumor metastasis in all 7 nodes 2. Omentum and peritoneum labelled as bladder dome, bilateral pelvis and ileocecum: metastatic adenocarcinoma 3. Appendix, incidental appendectomy: no pathological diagnosis	T3cN0M0 (III C)
25	E 1,2	f	38	endometrium: proliferative phase	Uterus with left adnexa, total abdominal hysterectomy with left salpingoophorectomy: 1) cervix: chronic nonspecific inflammation 2) endometrium: proliferative phase 3) myometrium : leiomyoma, intramural	
26	E 3,4	f	41	endometrium: secretory phase	Uterus, left ovary, total abdominal hysterectomy with left oophorectomy: 1) cervix: endocervical polyp 2) endometrium: secretory phase 3) myometrium: leiomyomas, intramural 4) ovary: mucinous cystadenoma with old hemorrhage	
27	E 5,6	f	27	endometrium: decidual change	Endometrium, Dilatation & curettage: decidual change, see note Note: Placental tissue is not identified in this specimen.	

A212: Uterus cancer tissues

No.	Coordinat		Sex	Age	Key word	Histological Diagnosis	TNM Stage
28	E	7,8	f	49	endometrium: endometrial polyp	Uterus, total abdominal hysterectomy: 1) cervix: chronic nonspecific inflammation 2) endometrium: - endometrial polyp - proliferative phase 3) myometrium: leiomyoma, intramural	
29	E	9,10	f	67	ovary: mucinous cystadenoma	Uterus with both adnexae, total abdominal hysterectomy with bilateral salpingoophorectomy: 1) cervix: chronic cervicitis, mild 2) endometrium: proliferative phase 3) salpinges, bilateral: no pathological diagnosis 4) soft tissue, clinically right ovary: consistent with paraovarian cyst 5) ovary, left: mucinous cystadenoma	
30	E	11,12	f	68	ovary: mucinous adenocarcinoma	1.Ovary, both, bilateral salpingoophorectomy (FS): mucinous adenocarcinoma (consistent with metastatic cholangiocarcinoma of the liver) 2. Fallopian tube, right: no pathological diagnosis 3. Fallopian tube, left : no pathological diagnosis	
31	F	1,2	f	49	endometrium hyperplasia	Endometrium, curettage: simple hyperplasia without atypia	
32	F	3,4	f	46	endometrium: simple hyperplasia	Uterine endometrium, biopsy: simple hyperplasia without atypia	
33	F	5,6	f	46	endometrium: atypical hyperplasia	Uterus, total abdominal hysterectomy with bilateral salpingoophorectomy: 1) cervix: chronic nonspecific inflammation 2) endometrium: atypical complex hyperplasia with squamous metaplasia involving adenomyotic foci 3) myometrium : - adenomyosis - leiomyomas, intramural and submucosal 4) ovaries, bilateral: no pathological diagnosis 5) fallopian tubes, bilateral: no pathological diagnosis	

A212: Uterus cancer tissues

No.	Coordinat	Sex	Age	Key word	Histological Diagnosis	TNM Stage
34	F 7,8	f	54	endometrium: endometrioid adenocarcinoma	<p>1. Uterus including both adenxae, total abdominal hysterectomy with bilateral salpingoophorectomy:</p> <ul style="list-style-type: none"> 1) cervix: chronic nonspecific inflammation 2) endometrium: endometrioid adenocarcinoma, grade I, type I with superficial invasion(confined to the upper half of myometrium), without vascular invasion 3) myometrium: adenomyosis 4) resection margins, right and left parametrium: free of tumor 5) ovary, right and left: fibrous adhesion due to previous pelvic inflammatory disease 6) fallopian tube, right and left: hydrosalpinx <p>2. Small intestine, segmental resection: fibrous adhesion due to pelvic inflammatory disease</p>	T1bN0M0 (I B)
35	F 9,10	f	57	ovary: mucinous adenocarcinoma	Ovary, left, frozen biopsy: mucinous adenocarcinoma	T1aN0M0 (I A)
36	G 1,2	f	69	endometrium: endometrioid carcinoma	<p>Uterus with both adnexae, total abdominal hysterectomy with bilateral salpingoophorectomy:</p> <ul style="list-style-type: none"> 1) cervix: chronic nonspecific inflammation 2) endomyometrium: endometrioid carcinoma, with <ul style="list-style-type: none"> - grade 1 - type I - superficial myometrial invasion (depth of invasion: 3/12 mm) - no vascular invasion. 3) ovaries, bilateral: no pathological diagnosis 4) fallopian tubes, bilateral: no pathological diagnosis 5) parametriums, bilateral: free of tumor 6) vaginal cuff: free of tumor 7) lymph nodes, right pelvic (0/6), left pelvic (0/10) and paraaortic (0/5): free of tumor metastasis in all 21 nodes 	T1bN0M0 (I B)

A212: Uterus cancer tissues

No.	Coordinat	Sex	Age	Key word	Histological Diagnosis	TNM Stage
37	G 3,4	f	50	endometrium: endometrioid adenocarcinoma	<p>Uterus with both adnexae, total abdominal hysterectomy with bilateral salpingoophorectomy:</p> <ol style="list-style-type: none"> 1) cervix: flat condyloma 2) endometrium: endometrioid adenocarcinoma, moderately differentiated (grade II), type II, with extensive vascular invasion and extension to the serosal surface resulting pelvic metastatic nodule formation 3) myometrium : leiomyomas, intramural 4) ovary, right: metastatic endometrioid carcinoma from the uterus 5) fallopian tube, right: subacute salpingitis 6) ovary and fallopian tube, left: free of tumor 7) cul de sac: chronic nonspecific inflammation with fibrosis 8) lymph node, left pelvic(1/2): metastatic carcinoma in one out of 2 lymph nodes 9) soft tissue, around the left pelvic node: metastatic endometrioid carcinoma 	T3N1M0 (III C)
38	G 5,6	f	56	endometrium: endometrioid adenocarcinoma	<p>Uterus including both adnexae, radical abdominal hysterectomy with bilateral salpingoophorectomy:</p> <ol style="list-style-type: none"> 1) cervix: chronic nonspecific inflammation 2) endometrium: <ul style="list-style-type: none"> - endometrioid adenocarcinoma, grade III, with focally deep myometrial invasion (Depth of invasion:12/15 mm) and frequent lymphovascular invasion, - no evidence of surrounding endometrioid hyperplasia 3) myometrium: leiomyomas, intramural 4) ovaries, both: no pathological diagnosis 5) fallopian tubes, both: no pathological diagnosis 6) parametria, both: free of tumor 7) vaginal cuff: free of tumor 8) lymph nodes, right pelvic (0/7) and left pelvic (0/13): free of tumor metastasis in all 20 nodes 	T1cN0M1 (IVB)

A212: Uterus cancer tissues

No.	Coordinat	Sex	Age	Key word	Histological Diagnosis	TNM Stage	
39	G	7,8	f	71	endometrium: carcinosarcoma	Uterus with both adnexae, total abdominal hysterectomy with bilateral salpingoophorectomy: 1) cervix: atrophy with erosion 2) endomyometrium: - malignant mixed millerian tumor (carcinosarcoma) composed of endometrioid carcinoma, grade 2(moderately differentiated) and heterologous sarcomatous component (rhabdomyosarcoma), focally - leiomyoma, intramural 3) resection margins, vaginal cuff: free of tumor 4) ovaries, bilateral: no pathological diagnosis 5) fallopian tube, bilateral: subacute salpingitis 6) lymph nodes: free of tumor (0/3) 7) appendix: mucinous cystadenoma with low grade dysplasia and excessive extracellular mucin formation, pseudomyxoma peritonei 8) results of immunohistochemical stain: Desmin, SMA: negative	
40	G	9,10	f	47	ovary: endometrioid adenocarcinoma	Uterus with both adnexae, total abdominal hysterectomy and bilateral salpingoophorectomy: 1) cervix: low grade squamous intraepithelial lesion (CIN grade I) 2) endometrium: polyps, premenstrual phase 3) myometrium: leiomyoma, subserosal 4) ovaries, bilateral: mixed carcinoma composed of transitional cell carcinoma, poorly differentiated, and endometrioid adenocarcinoma, bilateral, limited within ovarian capsule 5) fallopian tubes, both: no pathological diagnosis 6) parametrium, both: free of tumor 7) gutter, right and left: free of tumor 8) lymph nodes, right pelvic (0/10), left pelvic (0/6) and paraaortic (0/10): free of tumor metastasis in all 26 nodes	T1bN0M0 (I B)
41	H	1,2		49	myometrium: non neoplastic	myometrium: non neoplastic from H5,6	

A212: Uterus cancer tissues

No.	Coordinat	Sex	Age	Key word	Histological Diagnosis	TNM Stage
42	H 3,4	f	41	myometrium: leiomyoma	Uterus, total abdominal hysterectomy: 1) cervix: chronic cervicitis with squamous metaplasia 2) endometrium: secretory phase 3) myometrium: leiomyomas, intramural and subserosal	
43	H 5,6	f	49	myometrium: leiomyoma	Uterus, total abdominal hysterectomy: 1) cervix: chronic nonspecific inflammation with squamous metaplasia 2) endometrium: proliferative phase 3) myometrium : - leiomyomas, cellular, multiple, intramural - adenomyosis	
44	H 7,8	f	37	myometrium: leiomyosarcoma	Uterus including right adnexa, total abdominal hysterectomy with right salpingoophorectomy: 1) cervix: chronic nonspecific inflammation with squamous metaplasia 2) endometrium: - secretory phase - calcification 3) myometrium : smooth muscle tumor showing infiltrative margin, multifocally geographic necrosis, increased cellularity, moderate atypia and increased mitotic index (5/10HPF), morphologically consistent with leiomyosarcoma 4) resection margins, right and left: free of tumor 5) ovary, left: no pathological diagnosis 6) fallopian tube: no pathological diagnosis	
45	H 9,10	f	41	ovary: transitional cell carcinoma	Uterus, left adnexa, staging laparotomy: 1) cervix: serosal invasion of ovarian carcinoma 2) endometrium: proliferative phase 3) myometrium : myometrial direct and lymphatic invasion of ovarian carcinoma 4) fallopian tube, right: serosal invasion of ovarian carcinoma 5) ovary, right: mixed carcinoma composing endometrioid carcinoma and transitional cell carcinoma with extension to the parametrium, sigmoid colon and omentum 6) sigmoid colon, wedge resection: direct invasion of ovarian carcinoma to the outer muscle coat 7) omentum, total omentectomy: invasive implants of ovarian carcinoma	T3bNxM1 (IV)

A212: Uterus cancer tissues

No.	Coordinat	Sex	Age	Key word	Histological Diagnosis	TNM Stage
46	I 1,2	f	47	myometrium: adenomyosis	Uterus, total abdominal hysterectomy: 1) cervix: chronic cervicitis with squamous metaplasia 2) endometrium: proliferative phase 3) myometrium: adenomyosis	
47	I 3,4	f	38	myometrium: adenomatoid tumor	Uterus, total abdominal hysterectomy: 1) cervix: chronic nonspecific inflammation 2) endometrium: proliferative phase 3) myometrium: - leiomyoma, intramural - adenomatoid tumor	
48	I 5,6	f	43	myometrium: adenomatoid tumor	Uteurs, total abdominal hysterectomy: 1) cervix: chronic nonspecific inflammation 2) endometrium: proliferative phase 3) myometrium: - leiomyoma, intramural - adenomyosis - adenomatoid tumor	
49	I 7,8	f	47	myometrium: adenomatoid tumor	Uterus with both adnexae, total abdominal hysterectomy with bilateral salpingoophorectomy: 1) cervix: chronic nonspecific inflammation with squamous metaplasia 2) endometrium: proliferative phase 3) myometrium : - leiomyomas, intramural and subserosal - adenomyosis - adenomatoid tumor 4) ovary, right: mature teratoma 5) ovary, left : no pathological diagnosis 6) fallopian tube, right: no pathological diagnosis 7) fallopian tube, left : parovarian cysts	
50	I 9,10	f	57	ovary: transitional cell carcinoma	1.Ovary, both, bilateral salpingoophorectomy: 1) mixed carcinoma composing transitional cell carcinoma and serous adenocarcinoma, bilateral, with extension through ovarian capsule to extraovarian and paratubal soft tissue and extensive lymphovascular permeation 2) fallopian tube, right: metastatic transitional cell carcinoma 3) fallopian tube, left : free of tumor	T3bN1M1 (IV)