

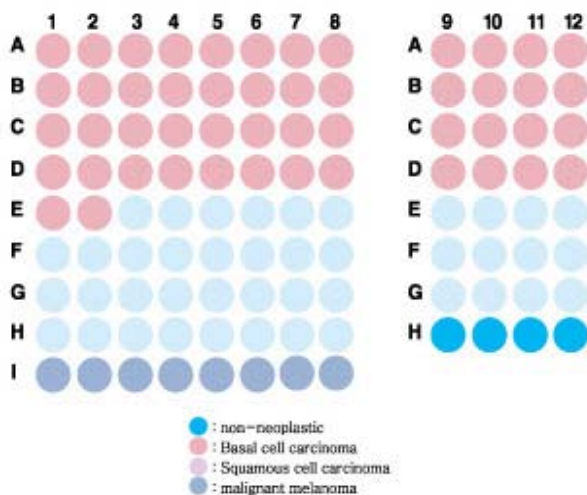
Specifications:

- No. of cases: 50
- Tissue type: Skin cancer tissues
- No. of spots: 2 spots from each cancer case (100 spots)
4 non-neoplastic spots (4 spots)
- Total spots: 104
- Corresponding normal tissues with cancers: Yes
- Diameter: 1.0 mm

Documents:

- Product specification: layout, summary of tissue spots
- H&E stained images
- Detailed pathological information

Layout:



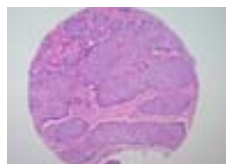
Summary of tissue spots

| No. | Coordinate | Sex | Age | Key Word | TNM Stage | |
|-----|------------|-------|-----|----------|--|---------------|
| 1 | A | 1,2 | m | 87 | basal cell carcinoma | T4N0M0 (III) |
| 2 | | 3,4 | m | 43 | basal cell carcinoma | T1N0M0 (I) |
| 3 | | 5,6 | f | 72 | basal cell carcinoma | T1N0M0 (I) |
| 4 | | 7,8 | m | 83 | basal cell carcinoma | T1N0M0 (I) |
| 5 | | 9,10 | m | 45 | basal cell carcinoma | T1N0M0 (I) |
| 6 | | 11,12 | m | 51 | basal cell carcinoma | T1N0M0 (I) |
| 7 | B | 1,2 | m | 59 | basal cell carcinoma | T1N0M0 (I) |
| 8 | | 3,4 | f | 76 | basal cell carcinoma | T1N0M0 (I) |
| 9 | | 5,6 | m | 81 | basal cell carcinoma | T1N0M0 (I) |
| 10 | | 7,8 | m | 70 | basal cell carcinoma | T1N0M0 (I) |
| 11 | | 9,10 | m | 76 | basal cell carcinoma | T1N0M0 (I) |
| 12 | | 11,12 | m | 69 | basal cell carcinoma seborrheic keratosis | T2N0M0 (II) |
| 13 | C | 1,2 | m | 66 | basal cell carcinoma | T2N0M0 (II) |
| 14 | | 3,4 | m | 62 | basal cell carcinoma | T2N0M0 (II) |
| 15 | | 5,6 | f | 74 | basal cell carcinoma | T1N0M0 (I) |
| 16 | | 7,8 | f | 82 | basal cell carcinoma | T1N0M0 (I) |
| 17 | | 9,10 | m | 49 | basal cell carcinoma | T1N0M0 (I) |
| 18 | | 11,12 | m | 41 | basal cell carcinoma | T1N0M0 (I) |
| 19 | D | 1,2 | m | 45 | basal cell carcinoma | T1N0M0 (I) |
| 20 | | 3,4 | m | 49 | basal cell carcinoma | T1N0M0 (I) |
| 21 | | 5,6 | f | 75 | basal cell carcinoma | T1N0M0 (I) |
| 22 | | 7,8 | m | 73 | basal cell carcinoma | T1N0M0 (I) |
| 23 | | 9,10 | m | 46 | basal cell carcinoma | T1N0M0 (I) |
| 24 | | 11,12 | m | 72 | basal cell carcinoma | T1N0M0 (I) |
| 25 | E | 1,2 | m | 88 | basal cell carcinoma | T1N0M0 (I) |
| 26 | | 3,4 | f | 78 | squamous cell carcinoma | T NxM1 (IV) |
| 27 | | 5,6 | m | 75 | squamous cell carcinoma | T4N0M0 (III) |
| 28 | | 7,8 | m | 66 | squamous cell carcinoma | T2N0M0 (II) |
| 29 | | 9,10 | m | 53 | squamous cell carcinoma | T2N0M0 (II) |
| 30 | | 11,12 | m | 74 | squamous cell carcinoma | T2N0M0 (II) |

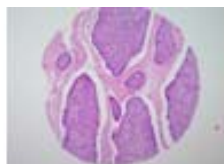Summary of tissue spots

| No. | Coordinate | Sex | Age | Key Word | TNM Stage |
|-----|------------|-----|-----|---|------------------|
| 31 | 1,2 | m | 48 | squamous cell carcinoma wartly carcinoma Bowen's disease lipogranuloma CIS paraffinoma | T2N0M0 (II) |
| 32 | 3,4 | m | 78 | squamous cell carcinoma | T2N0M0 (II) |
| 33 | 5,6 | m | 53 | squamous cell carcinoma | T3N0M0 (II) |
| 34 | 7,8 | m | 72 | squamous cell carcinoma | T3N0M0 (II) |
| 35 | 9,10 | f | 63 | metastatic carcinoma squamous cell carcinoma | T2N1M1 (IV) |
| 36 | 11,12 | f | 85 | squamous cell carcinoma | T1N0M0 (I) |
| 37 | 1,2 | f | 48 | squamous cell carcinoma | TisN0M0 (0) |
| 38 | 3,4 | m | 78 | squamous cell carcinoma | T1N0M0 (I) |
| 39 | 5,6 | m | 74 | squamous cell carcinoma | T1N0M0 (I) |
| 40 | 7,8 | m | 29 | squamous cell carcinoma | T3N0M0 (II) |
| 41 | 9,10 | f | 74 | squamous cell carcinoma | T1N0M0 (I) |
| 42 | 11,12 | f | 71 | squamous cell carcinoma | T1N0M0 (I) |
| 43 | 1,2 | m | 44 | squamous cell carcinoma | T4N2bM1 (IV) |
| 44 | 3,4 | f | 66 | squamous cell carcinoma | T1N0M0 (I) |
| 45 | 5,6 | m | 67 | squamous cell carcinoma | T1N0M0 (I) |
| 46 | 7,8 | m | 72 | malignant melanoma | T4aN2bM0 (III) |
| 47 | 9 | | | non-neopalastic, from A 9,10 | |
| 48 | 10 | | | non-neopalastic, from B 7,8 | |
| 49 | 11 | | | non-neopalastic, from D 1,2 | |
| 50 | 12 | | | non-neopalastic, from D 5,6 | |
| 51 | 1,2 | f | 49 | malignant melanoma | T4aN3M1 (IV) |
| 52 | 3,4 | m | 79 | malignant melanoma | T4aN3M1a (IV) |
| 53 | 5,6 | m | 56 | malignant melanoma | N1M1 (IV) |
| 54 | 7,8 | m | 51 | malignant melanoma | T4aN2bM1 (IV) |

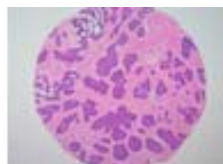
QC sheet_LOT#122120310121
Hematoxylin and Eosin staining



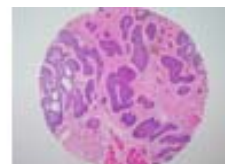
A1



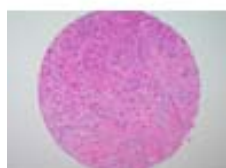A2



A3



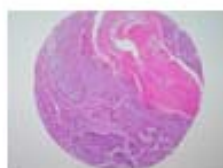
A4



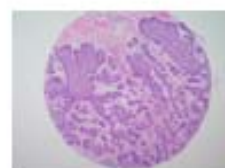
A5



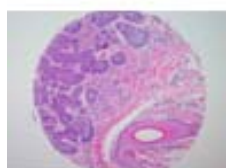
A6



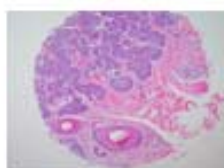
A7



A8



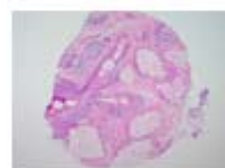A9



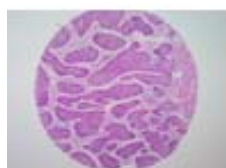A10



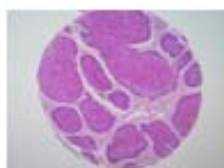
A11



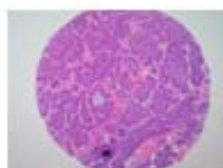
A12



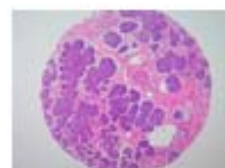B1



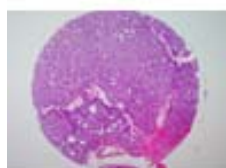
B2



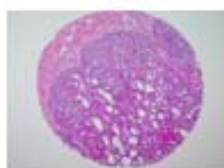B3



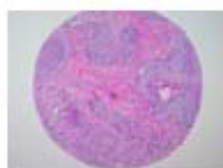B4



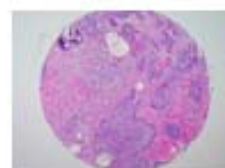
B5



B6



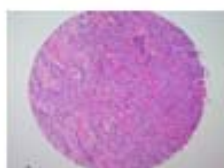
B7



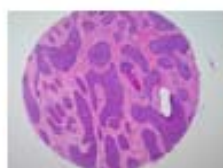
B8



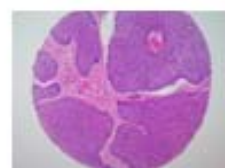
B9



B10

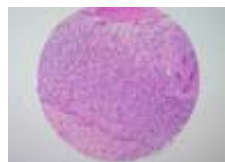

B11

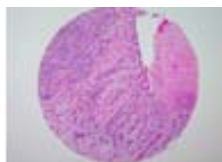


B12

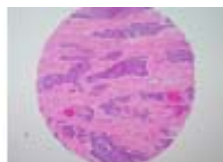
QC sheet_LOT#122120310121
Hematoxylin and Eosin staining



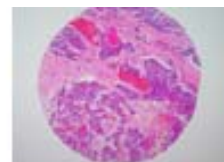
C1



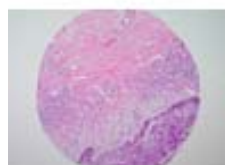
C2



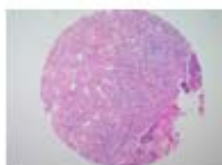
C3



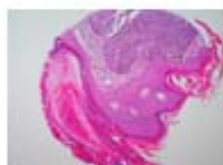C4



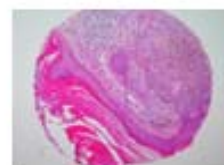C5



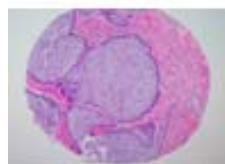
C6



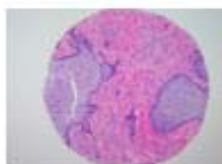C7



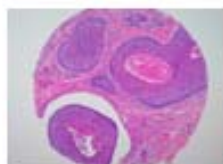
C8



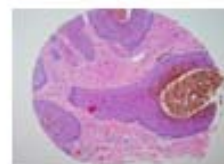
C9



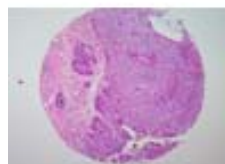
C10



C11



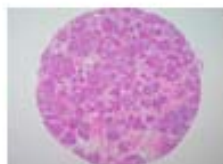
C12



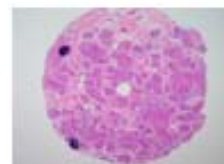
D1



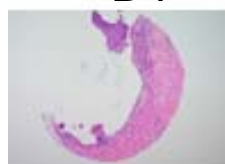D2



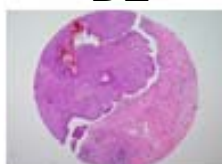
D3



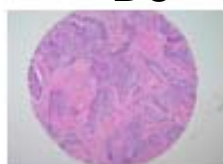
D4



D5



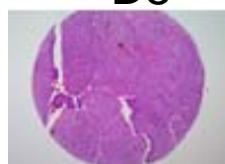
D6



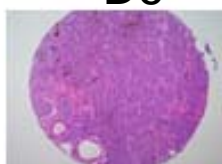
D7



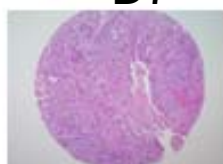
D8



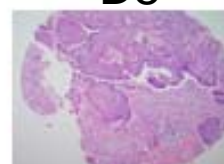D9



D10

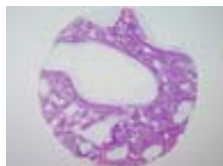

D11

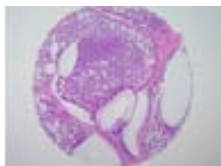


D12

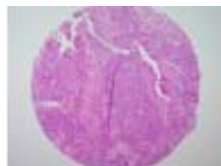
QC sheet_LOT#122120310121
Hematoxylin and Eosin staining



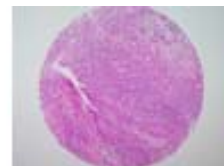E1



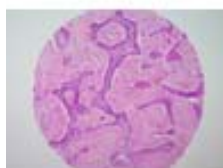E2



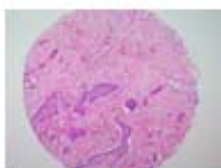
E3



E4



E5



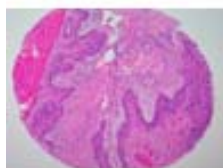
E6



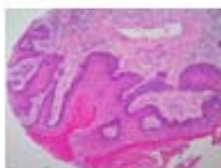E7



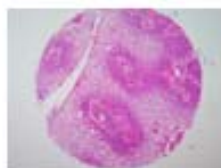
E8



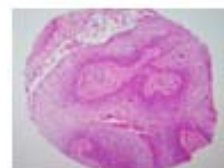
E9



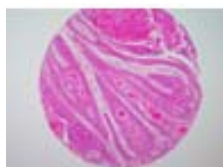E10



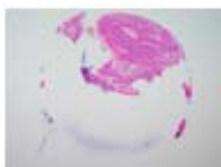
E11



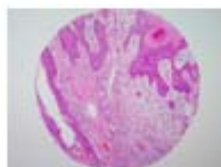E12



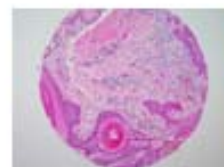F1



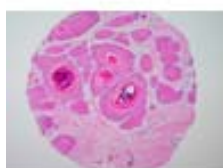F2



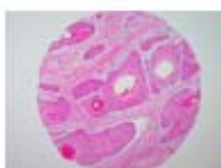F3



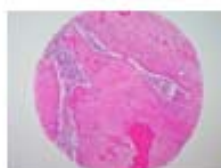F4



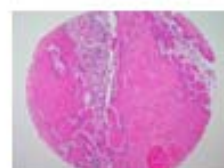
F5



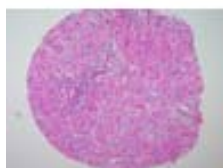F6



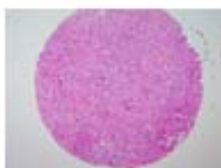F7



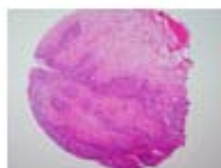
F8



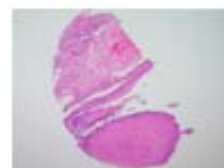F9



F10

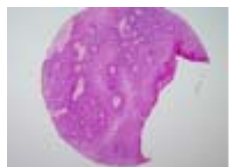

F11

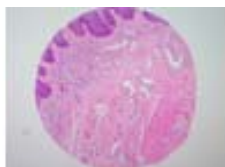

F12

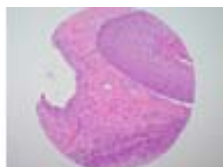QC sheet_LOT#122120310121
Hematoxylin and Eosin staining



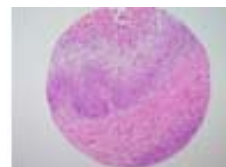
G1



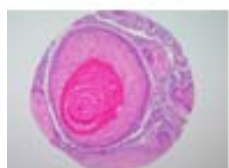G2



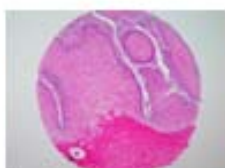G3



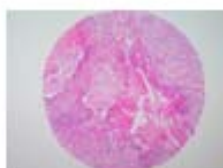
G4



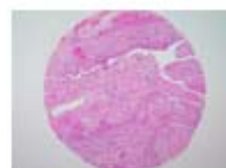G5



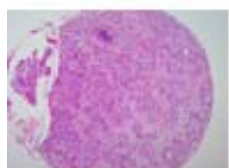
G6



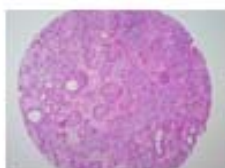G7



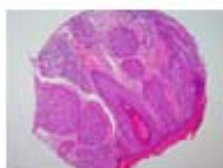G8



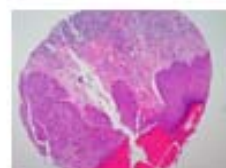
G9



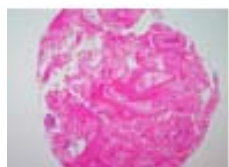G10



G11



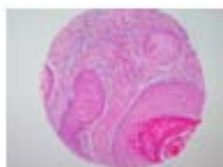G12



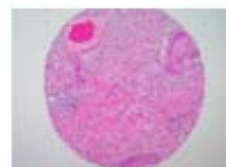
H1



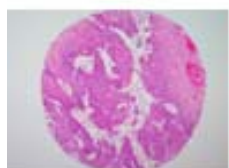
H2



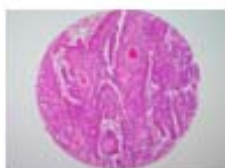H3



H4



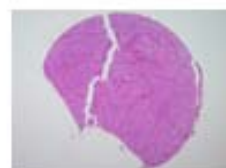
H5



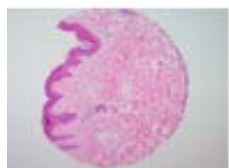
H6



H7



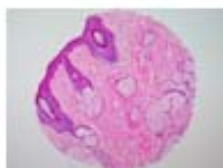H8



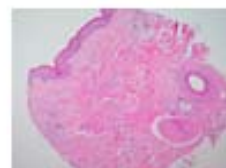H9



H10

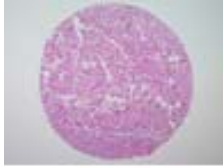

H11

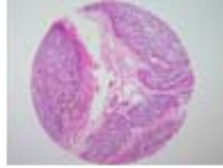


H12

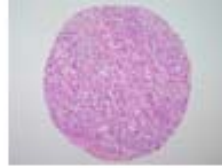QC sheet_LOT#122120310121
Hematoxylin and Eosin staining



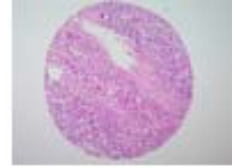
I1



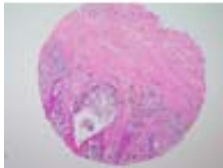
I2



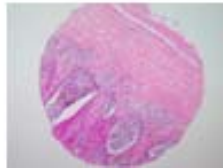I3



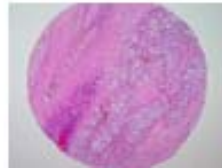I4



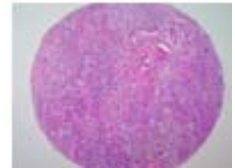I5



I6



I7



I8

A216: Skin cancer tissues

| No. | Coordinate | | Sex | Age | Key Word | Histological Diagnosis | Tumor size (cm) | TNM Stage | Treatment |
|-----|------------|-------|-----|-----|----------------------|--|-----------------|--------------|---------------|
| 1 | A | 1,2 | m | 87 | basal cell carcinoma | Skin, face, excision biopsy: 1) basal cell carcinoma extending deep to subcutaneous fat tissue and facial skeletal muscle 2) resection margin, superiol and lateral, free of tumor 3) resection margins, medial, inferiol, lateral and basal,extention of | 3.5 x 3.0 | T4N0M0 (III) | |
| 2 | A | 3,4 | m | 43 | basal cell carcinoma | Skin, excision, frozen biopsy: 1) basal cell carcinoma 2) resection margins, superior, inferior, lateral, base: free of tumor | 1.0 x 0.8 | T1N0M0 (I) | Wide excision |
| 3 | A | 5,6 | f | 72 | basal cell carcinoma | Skin, nasal dorsum, excision: 1) basal cell carcinoma 2) resection margins, superior, right and base: free of tumor 3) resection margins, inferior and left:Extension of carcinoma | 1.7 x 1.5 | T1N0M0 (I) | |
| 4 | A | 7,8 | m | 83 | basal cell carcinoma | Skin, left cheek, excision: 1) basal cell carcinoma 2) resection margins, all circumference and base: free of tumor | 2.0 x 2.0 | T1N0M0 (I) | Wide excision |
| 5 | A | 9,10 | m | 45 | basal cell carcinoma | Skin, scalp, occiput, excision: 1) basal cell carcinoma 2) resection margins, all circumference and base:free of tumor | 1.6 x 1.3 | T1N0M0 (I) | Wide excision |
| 6 | A | 11,12 | m | 51 | basal cell carcinoma | Skin, face, frozen excision: 1) basal cell carcinoma 2) resection margins, upper, lower and base: free of tumor 3) resection margin, lateral: extension of carcinoma | 1.3 x 1.0 | T1N0M0 (I) | Wide excision |
| 7 | B | 1,2 | m | 59 | basal cell carcinoma | Skin, infraorbital area, frozen excision: 1) basal cell carcinoma 2) resection margins, all circumference and base: free of tumor | 1.0 | T1N0M0 (I) | Wide excision |
| 8 | B | 3,4 | f | 76 | basal cell carcinoma | Skin, clinically from face, frozen biopsy: 1) basal cell carcinoma i) intact inferior resection margin (safety resection margin:less than 0.1 mm) ii) intact superior resection margin | 1.4 x 1.4 | T1N0M0 (I) | Wide excision |

A216: Skin cancer tissues

| No. | Coordinate | | Sex | Age | Key Word | Histological Diagnosis | Tumor size (cm) | TNM Stage | Treatment |
|-----|------------|-------|-----|-----|---|---|-----------------|-------------|---------------|
| 9 | B | 5,6 | m | 81 | basal cell carcinoma | Skin and subcutis, anterior chest, excision: 1) basal cell carcinoma, surgical resection margins are free of neoplasm | 1.5 x 1.2 | T1N0M0 (I) | |
| 10 | B | 7,8 | m | 70 | basal cell carcinoma | Skin, nasal alar, left, wide excision: 1) basal cell carcinoma 2) resection margins, lateral: free of tumor 3) resection margins, basa : free of tumor | 1.5 x 1.5 | T1N0M0 (I) | Wide excision |
| 11 | B | 9,10 | m | 76 | basal cell carcinoma | Skin, left medial cauthus, wide excision: 1) basal cell carcinoma 2) resection margin, base: Involvement of tumor 3) resection margins, lateral, medial, upper and lower: free of tumor | 0.5 | T1N0M0 (I) | Wide excision |
| 12 | B | 11,12 | m | 69 | basal cell carcinoma seborrhic keratosis | 1.Skin, nose, right, excision: 1) basal cell carcinoma 2) resection margins, upper and medial: extension of basal cell carcinoma 3) resection margins, lower, lateral and base: free of tumor 2.Skin, preauricular, excision: seborrhic keratosis 3.Cartilage, excision: free of tumor | 2.3 x 2.0 | T2N0M0 (II) | Wide excision |
| 13 | C | 1,2 | m | 66 | basal cell carcinoma | Skin, foot, excision: 1) No.1: basal cell carcinoma resection margins, all circumference and base: free of tumor 2) No.2: suggestive of chronic eczematous dermatitis without evidence of tumor | 2.5 x 2.0 | T2N0M0 (II) | Wide excision |

A216: Skin cancer tissues

| No. | Coordinate | | Sex | Age | Key Word | Histological Diagnosis | Tumor size (cm) | TNM Stage | Treatment |
|-----|------------|-------|-----|-----|----------------------|--|--------------------|-------------|---------------|
| 14 | C | 3,4 | m | 62 | basal cell carcinoma | 1.Skin, forehead, excision: basal cell carcinoma diffusely involving underlying resection margin 2.Soft tissue, medial canthal area, biopsy: invasion of basal cell carcinoma 3.Lymph node, preauricular, right (0/1): free of tumor | 2.5 x 2.0 | T2N0M0 (II) | Wide excision |
| 15 | C | 5,6 | f | 74 | basal cell carcinoma | Skin, leg, left, excision: 1) basal cell carcinoma, confined to the upper dermis 2) resection margins, proximal, distal, medial and lateral: free of tumor | 1.7 x 1.3 | T1N0M0 (I) | |
| 16 | C | 7,8 | f | 82 | basal cell carcinoma | Skin, leg, left, excision: 1) basal cell carcinoma 2) resection margin: free of tumor | 2.5 x 1.6 | T1N0M0 (I) | |
| 17 | C | 9,10 | m | 49 | basal cell carcinoma | Skin, site not specified, excision: 1) basal cell carcinoma 2) surgical resection margins are free of neoplastic involvement | 1.5 x 1.0 | T1N0M0 (I) | Wide excision |
| 18 | C | 11,12 | m | 41 | basal cell carcinoma | Skin, face, excision: 1) glabella, left: basal cell carcinoma, completely excised 2) forehead: free of tumor 3) nose: intradermal nevus | 1.5 x 1.5 | T1N0M0 (I) | Wide excision |
| 19 | D | 1,2 | m | 45 | basal cell carcinoma | Skin, nasolabial fold, excision: 1) basal cell carcinoma 2) resection margin : free of tumor | 1.8 x 1.3 x 1.0 | T1N0M0 (I) | |
| 20 | D | 3,4 | m | 49 | basal cell carcinoma | Skin, nasolabial fold, right, excision: 1) basal cell carcinoma, incompletely excised | 1.5 x 1.2 | T1N0M0 (I) | |
| 21 | D | 5,6 | f | 75 | basal cell carcinoma | Skin, scalp, mass excision: 1) basal cell carcinoma 2) resection margin: free of tumor | 0.8 x 0.5 | T1N0M0 (I) | |

A216: Skin cancer tissues

| No. | Coordinate | | Sex | Age | Key Word | Histological Diagnosis | Tumor size (cm) | TNM Stage | Treatment |
|-----|------------|-------|-----|-----|-------------------------|--|-----------------|------------------|---------------|
| 22 | D | 7,8 | m | 73 | basal cell carcinoma | Skin, nose, excision: 1) basal cell carcinoma 2) resection margins: free of tumor | 0.6 x 0.5 | T1N0M0 (I) | |
| 23 | D | 9,10 | m | 46 | basal cell carcinoma | Skin, medial canthus, right, excision: 1) basal cell carcinoma 2) resection margin: focal extension of carcinoma | 1.2 x 1.0 | T1N0M0 (I) | |
| 24 | D | 11,12 | m | 72 | basal cell carcinoma | Skin, left lower eyelid, excision: 1) basal cell carcinoma 2) resection margin: free of tumor | 0.7 x 0.7 | T1N0M0 (I) | |
| 25 | E | 1,2 | m | 88 | basal cell carcinoma | Skin, nose, frozen biopsy: 1) basal cell carcinoma 2) resection margin, upper: free of tumor 3) resection margin, deep: deep margin is closely approached by neoplasm within 0.1 mm range | 1.0 | T1N0M0 (I) | Wide excision |
| 26 | E | 3,4 | f | 78 | squamous cell carcinoma | Skin and soft tissue, axilla, left, excision: squamous cell carcinoma, primary or metastatic | 4.5 x 3.5 | T NxM1 (IV) | Radio therapy |

A216: Skin cancer tissues

| No. | Coordinate | | Sex | Age | Key Word | Histological Diagnosis | Tumor size (cm) | TNM Stage | Treatment |
|-----|------------|-------|-----|-----|-------------------------|---|--------------------|-----------------|---------------|
| 27 | E | 5,6 | m | 75 | squamous cell carcinoma | 1.Skin and parotid gland, wide excision and superficial parotidectomy: 1) squamous cell carcinoma, moderately differentiated, with extension to parotid gland 2) presence of perineural invasion 3) occasional lymphovascular permeation 4) regional lymph nodes: free of tumor in all 4 lymph nodes (0/4) | 2.0 x 1.8 | T4N0M0 (III) | Wide excision |
| 28 | E | 7,8 | m | 66 | squamous cell carcinoma | Skin, right leg, wide excision: Squamous cell carcinoma, well differentiated with 1) size : 3.5x2.5 cm 2) expanding growth 3) approaching to junction of dermo-subcutaneous fat tissue (depth of tumor: 8 mm) 4) intact deep resection margin (safety margin: 4 mm) | 3.5 x 2.5 x 0.8 | T2N0M0 (II) | |
| 29 | E | 9,10 | m | 53 | squamous cell carcinoma | Skin and soft tissue, leg, right, excision: 1) squamous cell carcinoma, well differentiated, extending to subcutaneous fat tissue 2) resection margin, base : free of tumor 3) resection margins, upper, lower and medial, separately submitted: free of tumor 4) resection margin, lateral, separately submitted: focal extension of squamous cell carcinoma | 5.0 x 3.0 | T2N0M0 (II) | Wide excision |
| 30 | E | 11,12 | m | 74 | squamous cell carcinoma | Skin, buttock, left, wide excision: 1) Invasive squamous cell carcinoma, moderately differentiated 2) resection margins, lateral and base : free of tumor | 4.0 x 3.0 x 1.0 | T2N0M0 (II) | Wide excision |

A216: Skin cancer tissues

| No. | Coordinate | Sex | Age | Key Word | Histological Diagnosis | Tumor size (cm) | TNM Stage | Treatment |
|-----|------------|-----|-----|--|--|--------------------|----------------|---------------|
| 31 | F 1,2 | m | 48 | squamous cell carcinoma warty carcinoma Bowen's disease lipogranuloma CIS paraffinoma | Skin and underlying tissue, perigenital area, excision: 1) condylomatous squamous cell carcinoma (warty carcinoma), invasive, with diffuse carcinoma in situ (Bowen's disease) 2) lipogranuloma, probably due to hypodermic injection of foreign substances such as paraffin, silicon, or wax 3) resection margins, superior, inferior, medial, lateral and basal | 3.5 x 3.0 x 1.7 | T2N0M0 (II) | Wide excision |
| 32 | F 3,4 | m | 78 | squamous cell carcinoma | Skin cheek, right, wide excision: 1) squamous cell carcinoma, well differentiated (size:2.5x1.5 cm) 2) resection margins, cephalic, caudal, medial, lateral and deep: free of tumor 3) solar elastosis and foreign body reaction to suture material | 2.5 x 1.5 | T2N0M0 (II) | Wide excision |
| 33 | F 5,6 | m | 53 | squamous cell carcinoma | Skin, right foot dorsum, wide excision: 1) squamous cell carcinoma, well differentiated, arising from Majolin's ulcer 2) resection margin, base:Involvement of squamous cell carcinoma 3) resection margins, proximal, distal, lateral and medial : free of tumor | 8.0 x 7.5 | T3N0M0 (II) | Wide excision |
| 34 | F 7,8 | m | 72 | squamous cell carcinoma | Skin, temporoparietal area, left, wide excision: well differentiated squamous cell carcinomasurgical margins are free of neoplastic change | 5.5 x 5.5 | T3N0M0 (II) | Wide excision |

A216: Skin cancer tissues

| No. | Coordinate | | Sex | Age | Key Word | Histological Diagnosis | Tumor size (cm) | TNM Stage | Treatment |
|-----|------------|-------|-----|-----|---|---|--------------------|------------------|---------------|
| 35 | F | 9,10 | f | 63 | metastatic carcinoma squamous cell carcinoma | Skin and soft tissue, right inguinal node, biopsy: diffuse infiltration of carcinoma with squamous differentiation, probably metastatic | 5.0 x 3.8 x 1.8 | T2N1M1 (IV) | |
| 36 | F | 11,12 | f | 85 | squamous cell carcinoma | Skin, left cheek, excision: 1) squamous cell carcinoma arising in actinic keratosis with focal superficial invasion 2) resection margin : free of tumor | 0.7 | T1N0M0 (I) | |
| 37 | G | 1,2 | f | 48 | squamous cell carcinoma | Skin, vulva, vulvectomy: 1) squamous cell carcinoma in situ 2) resection margins, all circumference and base : free of tumor | | TisN0M0 (0) | |
| 38 | G | 3,4 | m | 78 | squamous cell carcinoma | Skin, inguinal, multiple biopsy: invasive squamous cell carcinoma, well differentiated | 1.8 x 1.7 x 1.5 | T1N0M0 (I) | |
| 39 | G | 5,6 | m | 74 | squamous cell carcinoma | Skin with subcutaneous tissue, face, biopsy: squamous cell carcinoma, completely excised (safety margin : 2 mm apart from deep resection margin) | 2.2 x 1.2 | T1N0M0 (I) | |
| 40 | G | 7,8 | m | 29 | squamous cell carcinoma | Skin, occiput, biopsy: squamous cell carcinoma, well differentiated with involvement basal margin | 6.0 x 6.0 x 3.0 | T3N0M0 (II) | Wide excision |
| 41 | G | 9,10 | f | 74 | squamous cell carcinoma | Skin, mandible, left, excision: squamous cell carcinoma, with intact resection margins | 0.7 x 0.2 | T1N0M0 (I) | |

A216: Skin cancer tissues

| No. | Coordinate | | Sex | Age | Key Word | Histological Diagnosis | Tumor size (cm) | TNM Stage | Treatment |
|-----|------------|-------|-----|-----|-------------------------|---|------------------------|-----------------------|---------------|
| 42 | G | 11,12 | f | 71 | squamous cell carcinoma | Skin, cheek, right, excision: 1) squamous cell carcinoma in situ associated with actinic keratosis and focal invasion into the superficial dermis 2) resection margin, lateral : focal extension of carcinoma in situ | 0.7 | T1N0M0 (I) | |
| 43 | H | 1,2 | m | 44 | squamous cell carcinoma | Skin, chest, excision: 1) Squamous cell carcinoma, metastatic with i) size: 1.5 cm in the greatest diameter ii) involvement at resection margin | 1.5 | T4N2bM 1 (IV) | |
| 44 | H | 3,4 | f | 66 | squamous cell carcinoma | Skin, hand, right, excision: squamous cell carcinoma, well differentiated, with clean surgical margins | 1.8 x 0.8 | T1N0M0 (I) | |
| 45 | H | 5,6 | m | 67 | squamous cell carcinoma | Skin, right preauricular area, excision: 1) squamous cell carcinoma, invasive, well differentiated 2) resection margin : free of tumor | 2.0 x 1.6 x 1.6 | T1N0M0 (I) | Wide excision |
| 46 | H | 7,8 | m | 72 | malignant melanoma | Skin, back, excision: 1) malignant melanoma, nodular type, with extension to the reticular dermis (clark level IV) and depth of invasion 12 mm 2) resection margins, free of tumor | 50 x 50 x12 (mm) | T4aN2b M0 (III) | |
| 47 | H | 9 | m | 45 | | Non-neoplastic, from A 9,10 | | | |
| 48 | H | 10 | m | 70 | | Non-neoplastic, from B 7,8 | | | |
| 49 | H | 11 | m | 45 | | Non-neoplastic, from D 1,2 | | | |
| 50 | H | 12 | f | 75 | | Non-neoplastic, from D 5,6 | | | |

A216: Skin cancer tissues

| No. | Coordinate | | Sex | Age | Key Word | Histological Diagnosis | Tumor size (cm) | TNM Stage | Treatment |
|-----|------------|-----|-----|-----|--------------------|---|--------------------------|----------------------|--|
| 51 | I | 1,2 | f | 49 | malignant melanoma | Skin, left foot, excision: Malignant melanoma, nodular, with 1) maximal tumor thickness : 11 mm 2) Clark level V (involvement of subcutaneous fat tissue) 3) with features of regression at the adjacent skin | 55 x 25 x11 (mm) | T4aN3M 1 (IV) | |
| 52 | I | 3,4 | m | 79 | malignant melanoma | Skin, hand, thumb: 1) malignant melanoma, nodular type (clark level V or high risk according to bagley) with extention to the bone 2) resection margin, skin, free of tumor 3) resection margin, bone, free of tumor 4) resection margin, soft tissue and muscle, free of tumor 5) lymph nodes, supraclavicular (1/9), axilla (2/2), arm (2/2): metastatic melanoma to 5 out of 13 lymph nodes | 50 x 40 x 30 (mm) | T4aN3M 1a (IV) | Wide excision immunotherapy after operation |
| 53 | I | 5,6 | m | 56 | malignant melanoma | Skin, left heel, excision: 1) malignant melanoma, superficial spreading type, radial growth phase 2) resection margin: free of tumor | 1.2 x 7 (mm) | N1M1 (IV) | |
| 54 | I | 7,8 | m | 51 | malignant melanoma | Skin, excision, frozen biopsy: malignant melanoma, maximal tumor thickness: 5.5 mm with clean surgical margins and marked lymphoplasmacytic infiltration | 20 x 15 x 5.5 (mm) | T4aN2b M1 (IV) | |