

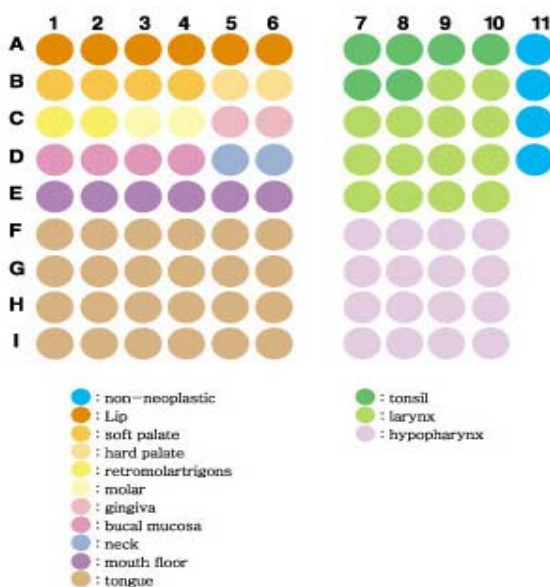
Specifications:

- No. of cases: 45
- Tissue type: Head and neck cancer tissues
- No. of spots: 2 spots from each cancer case (90 spots)
4 non-neoplastic spots (4 spots)
- Total spots: 94
- Corresponding normal tissues with cancers: Yes
- Diameter: 1.0 mm

Documents:

- Product specification: layout, summary of tissue spots
- H&E stained images
- Detailed pathological information

Layout:



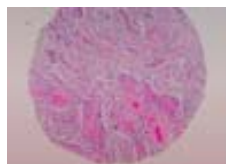Summary of tissue spots

No.	Coordinate	Sex	Age	Key Word	TNM Stage	
1	A	1,2	f	59	lip : squamous cell carcinoma	T2N2bM0 (IVA)
2		3,4	m	90	lip : squamous cell carcinoma	T2N0M0 (II)
3		5,6	m	63	lip : squamous cell carcinoma lymph node : tumor metastasis	T4N3M0 (IVB)
4		7,8	f	22	parathyroid : gland parathyroid carcinoma	*
5		9,10	f	45	parathyroid : gland parathyroid carcinoma	*
6		11			non-neoplastic, from A1, 2	
7	B	1,2	m	75	oral cavity : squamous cell carcinoma	T2N0M0 (III)
8		3,4	m	69	oral cavity : squamous cell carcinoma	T1N0M0 (I)
9		5,6	m	61	oral cavity : invasive squamous cell carcinoma	T2N0M0 (II)
10		7,8	f	31	trachea : adenoid cystic carcinoma	*
11		9,10	f	69	trachea : adenoid cystic carcinoma	*
12		11			non-neoplastic, from E3,4	
13	C	1,2	m	57	oral cavity : squamous cell carcinoma	T2N0M0 (II)
14		3,4	m	59	oral cavity : invasive squamous cell carcinoma	*
15		5,6	f	78	oral cavity : squamous cell carcinoma	T1N0M0 (I)
16		7,8	m	64	salivary gland : carcinoma	T2N0M0 (II)
17		9,10	m	57	salivary gland : carcinoma	T3N0M0 (III)
18		11			non-neoplastic, from E9, 10	
19	D	1,2	m	54	oral cavity : squamous cell carcinoma	T1N0M0 (I)
20		3,4	f	74	oral cavity : invasive squamous cell carcinoma	T3N0M0 (III)
21		5,6	f	67	oral cavity : invasive squamous cell carcinoma	T2N0M0 (II)
22		7,8	m	47	salivary gland : mucoepidermoid carcinoma	T3N2bM0 (IVA)
23		9,10	m	33	salivary gland : mucoepidermoid carcinoma	T3N0M0 (III)
24		11			non-neoplastic, from H7, 8	

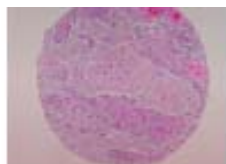
Summary of tissue spots

No.	Coordinate	Sex	Age	Key Word	TNM Stage	
25	E	1,2	m	64	oral cavity : squamous cell carcinoma lymph node : tumor metastasis	T1N1M0 (III)
26		3,4	m	65	oral cavity : invasive squamous cell carcinoma	T3N0M0 (III)
27		5,6	m	47	oral cavity : invasive squamous cell carcinoma	T2N0M0 (II)
28		7,8	m	69	esophagus : squamous cell carcinoma	T1N0M0 (I)
29		9,10	f	58	esophagus : squamous cell carcinoma	T2N0M0 (II A)
30	F	1,2	m	77	tongue : squamous cell carcinoma	T2N2cM0 (IVA)
31		3,4	m	70	tongue : squamous cell carcinoma	T2N1M0 (III)
32		5,6	m	77	tongue : squamous cell carcinoma	T2N2cM0 (IVA)
33		7,8	m	67	esophagus : squamous cell carcinoma	T2N0M0 (II A)
34		9,10	m	63	larynx : squamous cell carcinoma	T4aN0M0 (IVA)
35	G	1,2	f	49	thyroid gland : papillary carcinoma	T3N1aM0 (III)
36		3,4	f	28	thyroid gland : papillary carcinoma	T4N1bM0 (IVA)
37		5,6	f	47	thyroid gland : follicular carcinoma	T2NxM0
38		7,8	m	79	larynx : squamous cell carcinoma	T4aN0M0 (IVA)
39		9,10	m	50	larynx : squamous cell carcinoma	T4aN2cM0 (IVA)
40	H	1,2	f	60	thyroid gland : follicular carcinoma	T3NxM0
41		3,4	f	46	thyroid gland : medullary carcinoma	T3N1M0
42		5,6	f	35	thyroid gland : medullary carcinoma	T1NxM0
43		7,8	m	64	hypopharynx : squamous cell carcinoma	T3N1M0 (III)
44		9,10	m	62	hypopharynx : squamous cell carcinoma	T4N2cM1 (IVC)
45	I	1,2	f	58	tonsil : squamous cell carcinoma	T2N2bM0 (IVA)
46		3,4	m	53	tonsil : squamous cell carcinoma chronic sialadenitis lymph node : tumor metastasis	T3N2bM0 (IVA)
47		5,6	m	61	tonsil : squamous cell carcinoma	T2N2cM0 (IVA)
48		7,8	m	66	hypopharynx : squamous cell carcinoma lymph node : tumor metastasis	T3N2bM0 (IVA)
49		9,10	m	64	hypopharynx : squamous cell carcinoma lymph node : tumor metastasis	T3N1M0 (III)

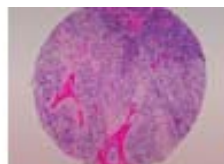QC sheet_LOT#122120312031
Hematoxylin and Eosin staining



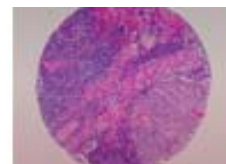
A1



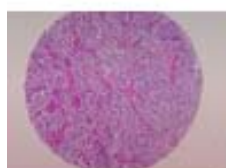A2



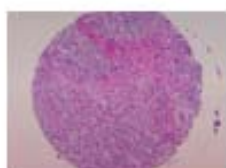A3



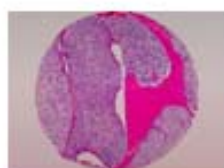A4



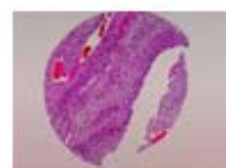
A5



A6



A7



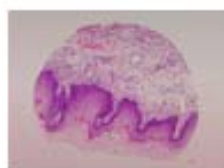A8



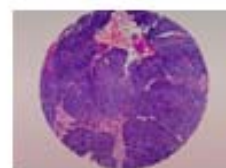A9



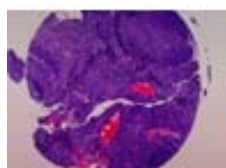
A10



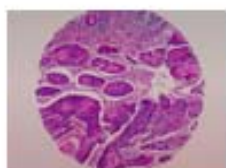
A11



B1



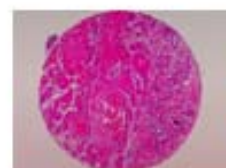B2



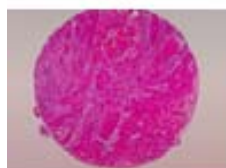B3



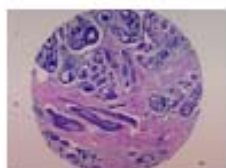
B4



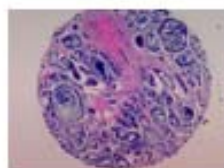
B5



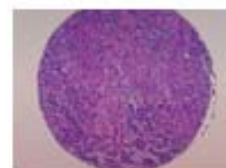B6



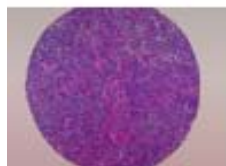B7



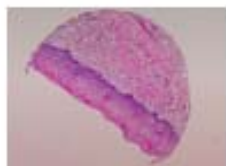B8



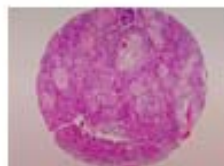
B9



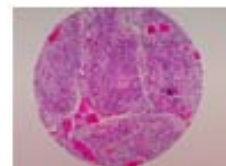
B10



B11

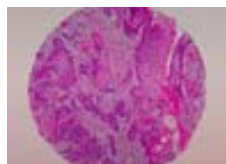


C1

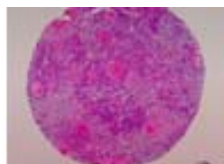


C2

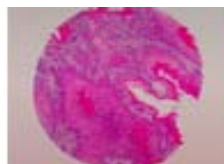
QC sheet_LOT#122120312031
Hematoxylin and Eosin staining



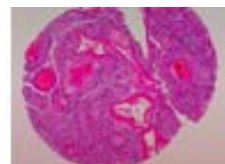
C3



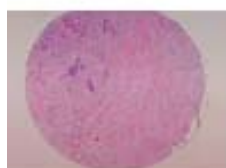C4



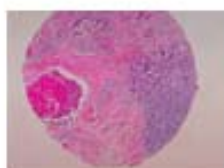
C5



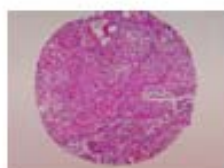
C6



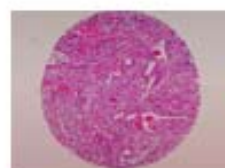
C7



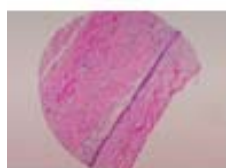C8



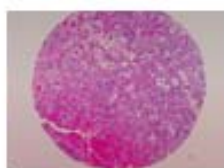
C9



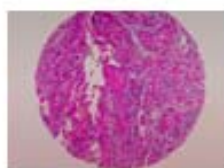
C10



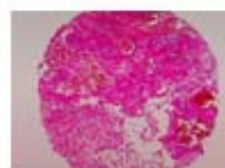C11



D1



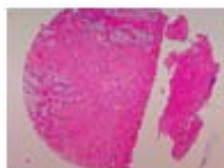
D2



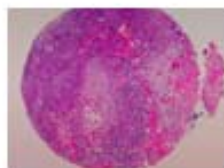
D3



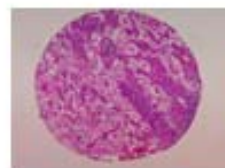
D4



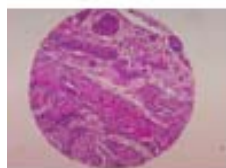
D5



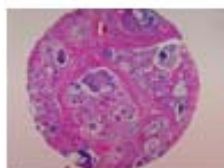
D6



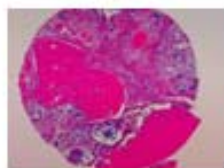
D7



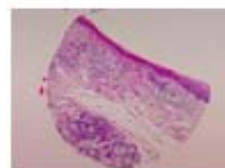
D8



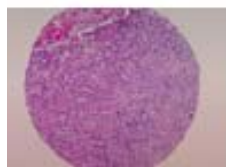
D9



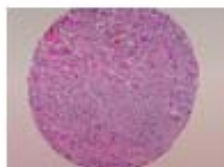D10



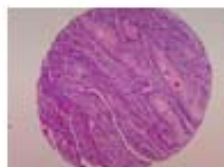D11



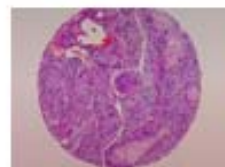
E1



E2

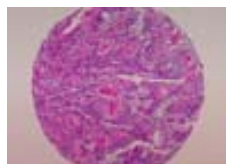


E3

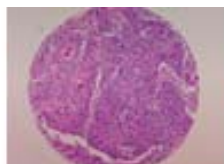


E4

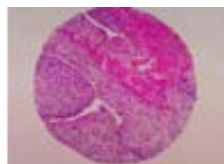
QC sheet_LOT#122120312031
Hematoxylin and Eosin staining



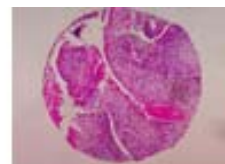
E5



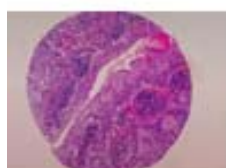E6



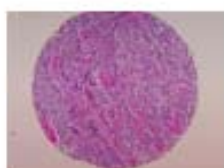E7



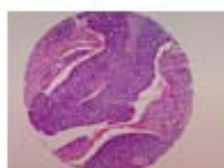
E8



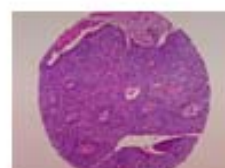
E9



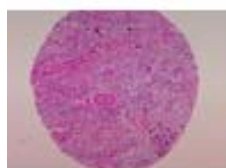E10



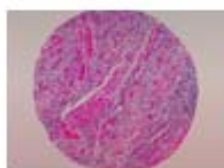F1



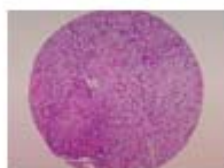
F2



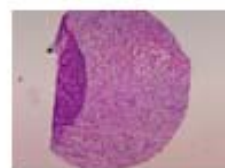F3



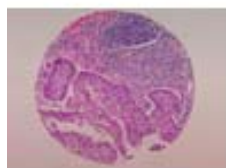
F4



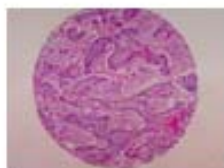
F5



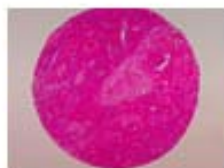F6



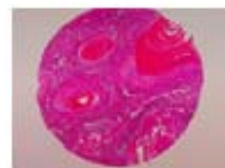F7



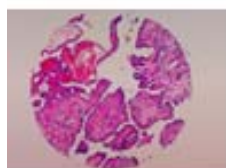
F8



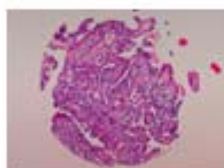
F9



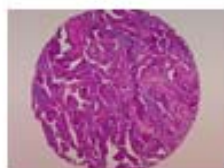
F10



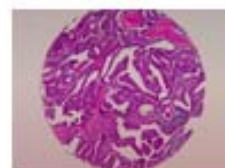
G1



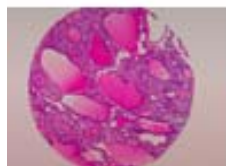G2



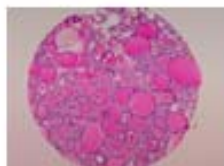
G3



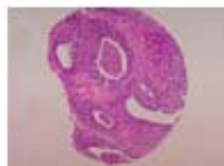G4



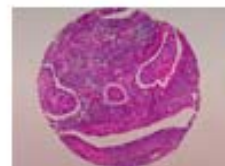G5



G6

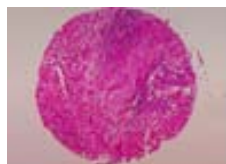

G7

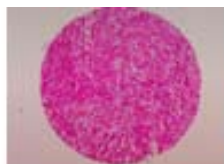

G8

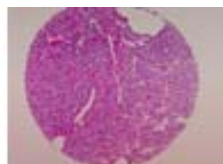
QC sheet_LOT#122120312031
Hematoxylin and Eosin staining



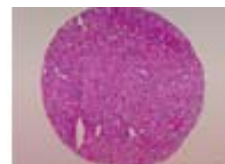G9



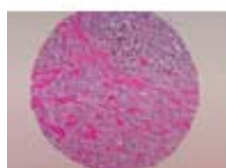G10



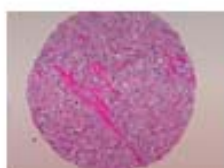H1



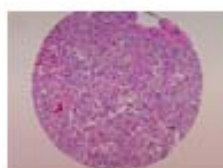
H2



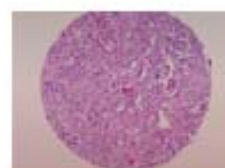
H3



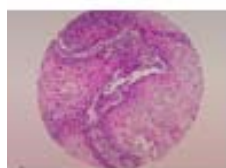H4



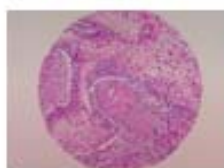
H5



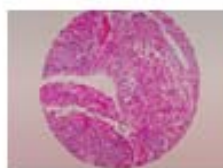
H6



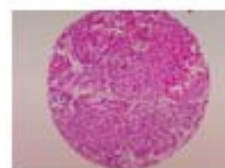
H7



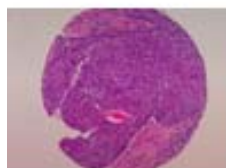
H8



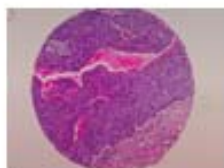H9



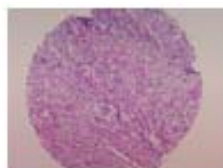H10



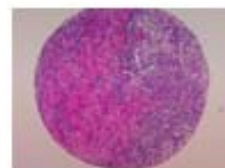I1



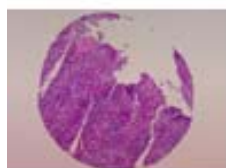
I2



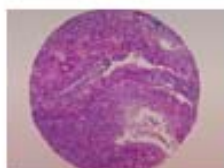
I3



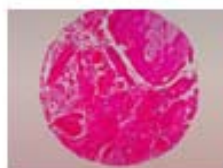
I4



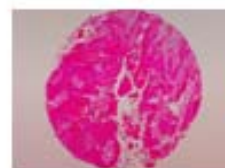I5



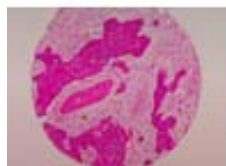
I6



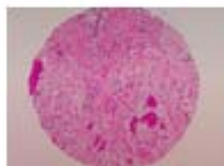
I7



I8



I9



I10

A219 : Head and neck cancer tissues

No.	Coordinate		Sex	Age	Key Word	Histological Diagonosis	TNM Stage
1	A	1,2	f	59	lip: squamous cell carcinoma	Lower lip, salivary gland and regional lymph node, radical excision: squamous cell carcinoma, well differentiated, with 1) size: 4.5x3.5x2 cm 2) penetration of underlying muscle layer 3) involvement deep resection margin 4) intact submandibular salivary gland 5) clear resection margins including right upper, lateral and lower, and left upper, lateral and lower resection margins 6) clear regional lymph nodes (0/38): right level I (0/4), level II (0/6), and level III (0/10), and left I (0/4), and level II (0/14)	T2N2bM0 (IVA)
2	A	3,4	m	90	lip: squamous cell carcinoma	Lip, lower, excision: papillary squamous cell carcinoma, well to moderately differentiated, with extension to muscle layer resection margin: free from tumor extension	T2N0M0 (II)
3	A	5,6	m	63	lip: squamous cell carcinoma lymph node: tumor metastasis	1. Lip, upper, radical excision: main mass:ulcerofungating squamous cell carcinoma, poorly differentiated, 1) size: 3x1.5 cm 2) suspicious lymphovascular formation 3) invasion depth: 1.2 cm 4) resection margins, upper, lower, right, left, basal: free of tumor 5) regional lymph nodes: tumor metastasis to 5 are of 53 (5/53) in detail, retrovascular, right (0/2), glandular, right (0/1),preglandular, right (1/3), retroglandular, right (1/4),prevascular, right (0/1), level IIa, right (1/3), level IIb, right (0/6), level III, right (0/6), retrovascular, left (1/1), retroglandular, left (0/2), glandular, left (0/0), prevascular, left (0/1), preglandular, left (0/3), level IIa, left (0/7), level IIb, left (0/4), level III, left (0/7), submental, right, left (1/2) 2. Salivary gland, submental: chronic nonspecific inflammation and free of tumor	T4N3M0 (IVB)

A219 : Head and neck cancer tissues

No.	Coordinate		Sex	Age	Key Word	Histological Diagonosis	TNM Stage
4	A	7,8	f	22	parathyroid: gland parathyroid carcinoma	Parathyroid gland, site unstated, parathyroidectomy: parathyroid gland neoplasm showing predominant solid growth pattern with dense fibrous bands, and extensive capsular and vascular invasion, consistent with parathyroid carcinoma extending to perithyroidal soft tissue, not into thyroid gland <Additional report > EM> Ultrastructural features of neoplastic cells are compatible with those of parathyroid gland origin: well developed Golgi, stacks of RER cisternae, ribosomes, mitochondria and neurosecretory granules. Some cells reveal glycogen particles.	*
5		9,10	f	45	parathyroid: gland parathyroid carcinoma	Parathyroid gland, thyroidectomy: parathyroid tumor with increased mitotic figure,suggestive of parathyroid carcinoma	*
6		11			non - neoplastic	Non-neoplastic, from A1, 2	
7	B	1,2	m	75	oral cavity: squamous cell carcinoma	Oral cavity, soft palate, incisional biopsy: basaloid squamous cell carcinoma	T2N0M0 (III)
8	B	3,4	m	69	oral cavity: squamous cell carcinoma	Oral cavity, soft palate, excision: squamous cell carcinoma, well differentiated	T1N0M0 (I)
9	B	5,6	m	61	oral cavity: invasive squamous cell carcinoma	1. Oral cavity, hard palate, wide excision: Invasive squamous cell carcinoma, moderately differentiated (maximum invasion depth: 8mm) 1) resection margin: focal extension of carcinoma 2) lymph nodes, neck, bilateral, dissection: submental (0/5), left preglandular (0/2), left retroglandular (0/3), left retrovascular (0/3), left IIA (0/10), left IIB (0/15), left III (0/13), right prevascular (0/2), right retrovascular (0/1), right IIA (0/7), right IIB (0/8) and right III (0/8) : (0/77): free of tumor 2. Submandibular glands, bilateral: free of tumor 3. Soft tissue, labelled as left prevascular, right preglandular, right retroglandular lymph node: free of tumor	T2N0M0 (II)

A219 : Head and neck cancer tissues

No.	Coordinate		Sex	Age	Key Word	Histological Diagonosis	TNM Stage
10	B	7,8	f	31	trachea: adenoid cystic carcinoma	<p>1. Larynx, trachea and thyroid gland, total laryngectomy: larynx and trachea: adenoid cystic carcinoma arising in the trachea with</p> <ol style="list-style-type: none"> 1) invasion through the cartilage layer and extension to the peritracheal fibrous tissue and lateral resection margin 2) extension into the larynx, intraglottic area 3) larynx, both vocal cord: free of tumor 4) resection margin, upper: free of tumor 5) resection margin, lower: extension of tumor <p>2. Thymus, labelled as left neck lymph node: free of tumor</p> <p>3. Soft tissue, labelled as left neck lymph node: extension of adenoid cystic carcinoma</p> <p>4. Pharyngeal mucosa, separately sent: free of tumor</p> <p>5. Thyroid gland, left: extension of the adenoid cystic carcinoma</p> <p>6. Thyroid gland, site unstated, separately sent: extension of the adenoid cystic carcinoma</p> <p>7. Esophagus, esophagectomy: free of tumor</p>	*
11	B	9,10	f	69	trachea: adenoid cystic carcinoma	<p>1. Trachea, resection: adenoid cystic carcinoma, predominantly solid infiltrating through cartilage and extending to peritracheal soft tissue and thyroid gland</p> <ol style="list-style-type: none"> 1) resection margin, upper: extension of adenoid cystic carcinoma 2) resection margin, lower: free of tumor <p>2. Thyroid gland, thyroidectomy:</p> <ol style="list-style-type: none"> 1) focal extension of adenoid cystic carcinoma 2) adenomatous hyperplasia 	*
12	B	11			non - neoplastic	Non-neoplastic, from E3,4	

A219 : Head and neck cancer tissues

No.	Coordinate		Sex	Age	Key Word	Histological Diagonosis	TNM Stage
13	C	1,2	m	57	oral cavity: squamous cell carcinoma	Oral cavity, retromolar trigone, wide excision: squamous cell carcinoma, well differentiated 1) resection margins, labelled as "retromolar margin" and "anterior pillar", "palatine tonsil", "posterior pillar", "tongue base", "soft palate": free of tumor 2) resection margin, labelled as "buccal mucosa": Involvement of tumor 3) specimens, labelled as "marginal mandibulectomy fragment", "mandible body": the additional report will follow after decalcification	T2N0M0 (II)
14	C	3,4	m	59	oral cavity: invasive squamous cell carcinoma	Oral cavity, 2nd, 3rd molar, left, biopsy: invasive squamous cell carcinoma, well differentiated	*
15	C	5,6	f	78	oral cavity: squamous cell carcinoma	Oral cavity, gingiva, left, wide excision: squamous cell carcinoma, well differentiated, invasive 1) resection margins, labelled as "posterior margin", "gingivolingual surface", "gingivobuccal surface", and "anterior margin": free of tumor 2) resection, base: extension of squamous cell carcinoma	T1N0M0 (I)
16	C	7,8	m	64	salivary gland: carcinoma	Salivary gland, parotid, frozen biopsy: carcinoma ex mixed tumor	T2N0M0 (II)
17	C	9,10	m	57	salivary gland: carcinoma	Salivary gland, parotid, right, excision: 1) consistent with carcinoma ex pleomorphic adenoma 2) regional lymph node: free of tumor in all nodes (0/5)	T3N0M0 (III)
18	C	11			non - neoplastic	Non-neoplastic, from E9, 10	
19	D	1,2	m	54	oral cavity: squamous cell carcinoma	Oral cavity, buccal mucosa, left, biopsy: invasive squamous cell carcinoma, well differentiated	T1N0M0 (I)

A219 : Head and neck cancer tissues

No.	Coordinate	Sex	Age	Key Word	Histological Diagonosis	TNM Stage
20	D 3,4	f	74	oral cavity: invasive squamous cell carcinoma	<p>1. Oral cavity, buccal mucosa, wide excision: invasive squamous cell carcinoma, well differentiated with extension to the subcutaneous fat tissue</p> <p>1) resection margins, all circumference: free of carcinoma</p> <p>2) lymph nodes, neck, dissection:submental Ia (0/6), retrovascular Ib (0/2), IIb (0/3), submandibular Ib (0/4), IIa (0/4) and III (0/10) : (0/29): free of tumor</p> <p>2. Soft tissue, labelled as prevascular Ib, preglandular Ib, and retroglandualr Ib: free of tumor</p> <p>3. Presence of salivary gland in retrovascular Ib, preglandular Ib, retroglandular Ib and submandibular: no pathological diagnosis</p>	T3N0M0 (III)
21	D 5,6	f	67	oral cavity: invasive squamous cell carcinoma	<p>1. Oral cavity, left wide excision with neck dissection, bilateral: invasive and in situ squamous cell carcinoma, moderately differentiated with focal extension to the tongue muscle</p> <p>1) maximum invasion depth: 5 mm</p> <p>2) resection margins, anterior, posterior, lateral and deep: free of tumor</p> <p>3) lymph nodes, left preglandular (0/1), left retrovascular (0/2), left level IIa (1/6), left level III (1/2), left level IV (0/2), left level V (0/4), right retrovascular (0/1), right prevascular (0/1), right level IIa (0/10), right level IIb (0/2), right level III (0/3) and submental (0/4) : (2/38) : metastatic squamous cell carcinoma in 2 out of 38 lymph nodes (0.8 cm in largest involved node)</p> <p>2. Tonsil, left: free of tumor</p> <p>3. Submandibular glands, bilateral: free of tumor</p> <p>4. Soft tissue, labelled as left retroglandular, left prevascular, left level IIb, right retroglandular and right preglandular: free of tumor</p>	T2N0M0 (II)
22	D 7,8	m	47	salivary gland: mucoepidermoid carcinoma	<p>1. Salivary gland, right submandibular, radical neck dissection: high grade mucoepidermoid carcinoma with areas of spindle cells (so called sarcomatoid carcinoma) and foci of salivary duct carcinoma, with extraparenchymal extension</p> <p>2. Soft tissue, separately submitted as "infrahyoid muscle" and "submandibular gland bed": free of tumor</p> <p>3. Regional lymph node, level I (0/17), level II (0/12), level III (0/6), level IV (0/11) : (0/46): free of tumor</p>	T3N2bM0 (IVA)

A219 : Head and neck cancer tissues

No.	Coordinate		Sex	Age	Key Word	Histological Diagnosis	TNM Stage
23	D	9,10	m	33	salivary gland: mucoepidermoid carcinoma	1. Salivary gland, parapharyngeal space, excision: 1) mucoepidermoid carcinoma, intermediate grade 2) resection margin: extension of carcinoma 2. Submandibular gland, separately submitted: free of tumor	T3N0M0 (III)
24	D	11			non - neoplastic	Non-neoplastic, from H7, 8	
25	E	1,2	m	64	oral cavity: squamous cell carcinoma lymph node: tumor metastasis	Oral cavity, floor of mouth and mandible, wide excision with RND and mandibulectomy: 1) floor of mouth : post-biopsy status with focal residual squamous cell carcinoma 2) resection margin, base: free of tumor 3) lymph nodes and margins: - 1 (right level IIb lymph node): free of tumor (0/3) - 2 (right level IIa lymph node): free of tumor (0/1) - 3 (right level III, SCM muscle): free of tumor in node (0/2) and SCM - 4 (right level IV lymph node): free of tumor in node (0/2) and skeletal muscle - 5 (right level V lymph node): free of tumor (0/4) - 6 (right SMG): free of tumor - 7 (pretracheal lymph node): free of tumor (0/0) - 8 (left SMG): free of tumor in node (0/3) and SMG - 9 (left level IIb lymph node): free of tumor (0/8) -10 (left level IIa lymph node): free of tumor (0/6) -11 (left level IV lymph node): tumor metastasis (1/7) -12 (left level III lymph node): free of tumor (0/4) -13 (lateral side, mouth floor mucosa) margin: free of tumor -14 (anterior side, mouth floor mucosa) margin: free of tumor -16 (posterior side, mouth floor mucosa), margin: free of tumor -17 (medial side mouth), margin: free of tumor	T1N1M0 (III)

A219 : Head and neck cancer tissues

No.	Coordinate		Sex	Age	Key Word	Histological Diagnosis	TNM Stage
26	E	3,4	m	65	oral cavity: invasive squamous cell carcinoma	<p>1. Oral cavity, floor of mouth with lymph nodes, neck, excision with dissection: invasive squamous cell carcinoma, well differentiated (invasion depth: about 8 mm)</p> <p>1) resection margins, lateral and base: free of tumor</p> <p>2) lymph nodes, labelled as right retrovascular (0/1), right level IIa (0/4), right level IIb (0/9), right level III (0/23), left prevascular (0/2), left retrovascular (0/1), left retroglandular (0/2), left level IIa (0/2), left level IIb (0/12) and left level III (0/6) : (0/62): free of tumor</p> <p>2. Soft tissue, labelled as right prevascular, right preglandular: free of tumor</p> <p>3. Salivary glands, labelled as right glandular, right retroglandular, left preglandular and left glandular: free of tumor</p>	T3N0M0 (III)
27	E	5,6	m	47	oral cavity: invasive squamous cell carcinoma	<p>1. Oral cavity, mouth floor with lymph nodes, neck, bilateral, excision and dissection: invasive squamous cell carcinoma, moderately differentiated with extension to the skeletal muscle (maximum invasion depth: 0.8cm)</p> <p>1) resection margins, all circumference and base: free of tumor</p> <p>2) lymph nodes, labelled as submental (0/2), right prevascular (0/1), right retrovascular (0/1), right preglandular (0/1), right retroglandular (0/1), right level IIA (0/8), right level IIB (0/5), right level III (0/4), left prevascular (0/1), left retrovascular (0/1), left preglandular (0/1), left retroglandular (0/1), left level IIA (0/4), left level IIB (0/6) and left level III (0/4) : (0/41): free of tumor</p> <p>2. Submandibular gland, bilateral: free of tumor</p>	T2N0M0 (II)

A219 : Head and neck cancer tissues

No.	Coordinate		Sex	Age	Key Word	Histological Diagonosis	TNM Stage
28	E	7,8	m	69	esophagus: squamous cell carcinoma	<p>1. Esophagus, esophagectomy: fungating squamous cell carcinoma, well differentiated with focal necrosis with</p> <ol style="list-style-type: none"> 1) tumor extension to the submucosa 2) no lymphovascular permeation 3) no perineural invasion 4) adjacent squamous cell carcinoma in situ 5) resection margins, proximal and distal: free of tumor 6) regional lymph nodes, paraaortic (0/2), inferior pulmonary ligament (0/3), hilar (0/8) paraesophageal (0/2) : (0/15): free of tumor in all 15 lymph nodes.- anthracosilicosis <p>2. Soft tissue, labelled as "paraspinal mass": myelolipoma</p> <p>3. Omentum: free of tumor</p>	T1N0M0 (I)
29	E	9,10	f	58	esophagus: squamous cell carcinoma	<p>Esophagus, esophagectomy: squamous cell carcinoma, moderately differentiated with extension to the proper muscle</p> <ol style="list-style-type: none"> 1) resection margins, proximal and distal: free of tumor 2) lymph node, regional (0/1): free of tumor 	T2N0M0 (II A)
30	F	1,2	m	77	tongue: squamous cell carcinoma	<p>Tongue base, wide excision: squamous cell carcinoma, well differentiated with involvement of ventral tongue side resection margin, see note</p> <ol style="list-style-type: none"> 1) resection margin, right and left: free of tumor 2) lymph nodes, neck, dissection: <ul style="list-style-type: none"> - right: level I (0/1), level II (1/8), level III (0/3), level IV (0/5): - left: level I (0/0), level II (0/6), level III (1/8), level IV (0/6), level V (0/3): metastatic <p>squamous cell carcinoma in 2 out of 40 lymph nodes</p> <p>Note: Tumor approaches to the mandible side resection margin within 1mm</p>	T2N2cM0 (IVA)

A219 : Head and neck cancer tissues

No.	Coordinate		Sex	Age	Key Word	Histological Diagonosis	TNM Stage
31	F	3,4	m	70	tongue: squamous cell carcinoma	Tongue with neck lymph node, SCM muscle, hemiglossectomy with radical neck dissection: 1) tongue: sarcomatoid squamous cell carcinoma 2) resection margin, underlying: presence of squamous cell carcinoma 3) lymph nodes, level I (0/2), II (1/2), III (1/4), IV (0/2) and V (0/3): metastasis in 2 out of 13 nodes 4) submandibular gland: free of tumor 5) SCM muscle: free of tumor	T2N1M0 (III)
32	F	5,6	m	77	tongue: squamous cell carcinoma	1. Tongue, excision: poorly differentiated squamous cell carcinoma (size,3.5x1.5 cm), see note 1 regional lymph node, left neck, radical neck dissection level I (0/1), level II (1/15), level III (0/28), level IV (0/12), level V (0/6), (1/62), metastatic squamous cell carcinoma in one out of 62 nodes (size of involved node,3.5 cm), see note 2 2. Salivary gland, lingual and submandibular: free of tumor 3. Skeletal muscle, sternocleidomastoid:, free of tumor 4. Jugular vein: free of tumor Note 1> The tumor involves lateral and basal resection margins. It is 2mm apart from anterior margin and 1 cm from posterior margin. Note 2> One lymph node contains bland-looking thyroid follicles. Although there are no papillary configuration, nuclear groove and intranuclear inclusion, the possibility of metastatic papillary carcinoma of thyroid is suspected. Investigation of thyroid gland is needed	T2N2cM0 (IVA)
33	F	7,8	m	67	esophaus: squamous cell carcinoma	Esophagus, esophagectomy: squamous cell carcinoma, moderately differentiated with extension to muscularis propria and occasional lymphatic permeation 1) resection margins, proximal and distal: free of tumor 2) regional lymph nodes, No.1 (0/2), No.2 (0/4) : (0/6): free of tumor	T2N0M0 (II A)
34	F	9,10	m	63	larynx: squamous cell carcinoma	Larynx, hemilaryngectomy: squamous cell carcinoma, well differentiated, with extension to thyroid cartilage	T4aN0M0 (IVA)

A219 : Head and neck cancer tissues

No.	Coordinate		Sex	Age	Key Word	Histological Diagonosis	TNM Stage
35	G	1,2	f	49	thyroid gland: papillary carcinoma	<p>1. Thyroid glands, bilateral with lymph nodes, right anterolateral, total thyroidectomy with dissection:</p> <ol style="list-style-type: none"> 1) papillary carcinoma involving both lobes (intrathyroidal metastasis) and penetrating capsule with extension to the perithyroidal soft tissue 2) resection margin: free of tumor 3) lymph nodes, No.3,4 (0/14), No.6,7 (1/4) : (1/18): metastatic papillary carcinoma in 1 out of 18 lymph nodes <p>2. Soft tissue, submitted as No.6,7 lymph node: presence of papillary carcinoma</p>	T3N1aM0 (III)
36	G	3,4	f	28	thyroid gland: papillary carcinoma	<p>Thyroid gland, both, total thyroidectomy:</p> <ol style="list-style-type: none"> 1) papillary carcinoma in the right lobe with extension to the perithyroidal soft tissue 2) lymph nodes, No.1 (2/2), No.2 (2/2), right recurrent laryngeal nerve (10/15) and regional (4/4) : (18/23): tumor metastasis to 18 out of 23 lymph nodes with perinodal soft tissue extension 	T4N1bM0 (IVA)
37	G	5,6	f	47	thyroid gland: follicular carcinoma	<p>Thyroid gland, thyroidectomy:</p> <ol style="list-style-type: none"> 1) smaller mass: follicular carcinoma, intrathyroidal 2) larger mass: adenomatous hyperplasia 	T2NxM0
38	G	7,8	m	79	larynx: squamous cell carcinoma	<p>Larynx with regional lymph nodes, total laryngectomy and radical neck dissection: squamous cell carcinoma, moderately differentiated, with extensive necrosis and marked fibrosis, probably due to radiation therapy with</p> <ol style="list-style-type: none"> 1) size: 4.5x4.5x4 cm 2) expanding growth 3) involvement at supraglottis, glottis and subglottis 4) invasion through the cricoid and thyroid cartilages and extension to other tissue beyond the larynx including soft tissue and skeletal muscle of the neck, and perithyroidal soft tissue (T4) 5) extension to superior resection margin (epiglottis) 6) intact anterior, posterior and inferior (trachea) resection margins 7) no metastasis to regional lymph nodes (right level II (0/6), right level III (0/6), right level IV (0/10), left level II (0/2), left level III (0/8), left level IV (0/8)) 8) intact left lobe of thyroid gland and hyoid bone from tumor 	T4aN0M0 (IVA)

A219 : Head and neck cancer tissues

No.	Coordinate	Sex	Age	Key Word	Histological Diagnosis	TNM Stage
39	G 9,10	m	50	larynx: squamous cell carcinoma	Larynx, hyoid bone, thyroid gland and regional lymph nodes, total laryngectomy, thyroidectomy and radical neck dissection: ulceroinfiltrative squamous cell carcinoma, poorly differentiated, in glottis and subglottis with 1) size: 4.5x3.5 cm in two dimension 2) infiltrative and destructive growth 3) penetration of thyroid cartilage and extension to the surrounding soft tissue and thyroid gland 4) intact resection margins including anterior, posterior, superior and inferior resection margins 5) metastasis to 2 out of 75 regional lymph nodes (paratracheal (0/2), left level IIa (0/1), left level II (0/12), left level III (1/6), left level IV (0/28), right level IIa (0/1), right level II (0/8), right level III (0/4) and right level IV (1/13)) 6) intact hyoid bone from tumor	T4aN2cM0 (IVA)
40	H 1,2	f	60	thyroid gland: follicular carcinoma	Thyroid, thyroidectomy and frozen biopsy: 1) encapsulated follicular carcinoma with capsular and vascular invasion 2) microscopic papillary carcinoma, separated from main tumor (follicular carcinoma)	T3NxM0
41	H 3,4	f	46	thyroid gland: medullary carcinoma	Thyroid gland, thyroidectomy: medullary carcinoma, focally extending beyond the capsule Note:congo-red stain reveals stromal amyloid deposit, Immunohistochemical stain for calcitonin show strong positivity of neoplastic cells, which support the diagnosis of medullary carcinoma. EM: ultrastructural findings are compatible with medullary carcinoma showing numerous round, electron dense, membrane bound, neurosecretory type granules.	T3N1M0
42	H 5,6	f	35	thyroid gland: medullary carcinoma	1. Thyroid, thyroidectomy, frozen biopsy: medullary carcinoma, intrathyroid with multifocal C-cell hyperplasia in adjacent thyroid parenchyme, in associated with MEN IIa 2. Parathyroid gland, right upper and left upper: chief cell hyperplasia	T1NxM0

A219 : Head and neck cancer tissues

No.	Coordinate	Sex	Age	Key Word	Histological Diagonosis	TNM Stage
43	H 7,8	m	64	hypopharynx: squamous cell carcinoma	<p>1. Hypopharynx: invasive squamous cell carcinoma, well differentiated with extension to the larynx and surrounding soft tissue</p> <p>1) resection margin, upper pharyngeal: free of tumor but shows, moderate dysplasia 2) resection margin, lateral pharyngeal: free of tumor 3) resection margin, lower trachea: free of tumor 4) resection margin, posterior: free of tumor 5) regional lymph nodes, level I (0/2), right level II (2/6), right posterosuperior (0/0), right level III (0/8), right level IV (0/3), right level IV (0/6), thyroid (0/4), left level II (1/5), left level III (0/14), left level IV (0/2): metastatic carcinoma to 3 out of 50 lymph nodes</p> <p>2. Salivary gland, right submandibular: free of tumor 3. Thyroid: free of tumor (extends to the capsule of the thyroid but not invaded within parachyme)</p>	T3N1M0 (III)
44	H 9,10	m	62	hypopharynx: squamous cell carcinoma	<p>1. Hypopharynx, larynx, trachea, hyoid, thryoid gland, total laryngopharyngectomy: squamous cell carcinoma, well-differentiated, right pyriform sinus,with</p> <p>1) lateral extension to pharyngeal muscle 2) extension to submucosa of vocal cord 3) resection margin, pharyngeal, lateral, tracheal: free of tumor</p> <p>2. Thyroid gland, right and hyoid bone: free of tumor</p>	T4N2cM1 (IVC)
45	I 1,2	f	58	tonsil: squamous cell carcinoma	<p>1. Tonsil, left, wide excision: papillary squamous cell carcinoma, invasive, moderately differentiated</p> <p>1) resection margin, basal: extension to tumor 2) resection margin, lateral: moderate epithelial dysplasia 3) lymph nodes, left, level I (0/2), level II (2/15), level III (0/9), level IV (0/15), level V (0/16), radical neck dissection (2/57): metastatic carcinoma in 2 out of 57 lymph nodes</p> <p>2. Submandibular gland: free of tumor 3. Skeletal muscle: free of tumor</p>	T2N2bM0 (IVA)

A219 : Head and neck cancer tissues

No.	Coordinate		Sex	Age	Key Word	Histological Diagonosis	TNM Stage
46	I	3,4	m	53	tonsil: squamous cell carcinoma chronic sialadenitis lymph node: tumor metastasis	Tonsil, radical excision: squamous cell carcinoma, poorly differentiated, with 1) surface ulceration 2) size: 3.5x1.8 cm 3) expanding growth 4) lymphovascular permeation: negative 5) resection margins, pharynx, upper gingiva, retromolar trigone, tonsil: free of tumor 6) resection margin, base: free of tumor, but nearly attached 7) regional lymph nodes: tumor metastasis to 2 out of 39 (2/39), in detail, prevascular (0/0), retrovascular (0/2), preglandular (0/1), retroglandular (0/3), SMG(chronic sialadenitis and its node (0/1), level IIA (1/5), level IIB (1/13), level III (0/10), level IV (0/4)	T3N2bM0 (IVA)
47	I	5,6	m	61	tonsi: squamous cell carcinoma	1. Tonsil, left, excision: squamous cell carcinoma, moderately differentiated, involving surgical margins, with prominent lymphovascular permeation 1) lymph node, right, neck, dissection: level I (0/10), level II (0/34), level III (0/19) : (0/53) : free of tumor 2) lymph node, left, neck dissection: level I (0/10), level II (2/9), level III (1/14), level IV (0/1), level V (0/1) : (3/51) : metastatic squamous cell carcinoma in 3 out of 51 nodes,see note 2. Submandibular glands, both: free of tumor Note: The large metastatic cancer at level II shows conglomerulation of metastatic nodes. So number of nodes involved by the tumor is not quite exact.The metastatic tumor extends to extranodal tissue and skeletal muscle bundles.	T2N2cM0 (IVA)

A219 : Head and neck cancer tissues

No.	Coordinate	Sex	Age	Key Word	Histological Diagonosis	TNM Stage	
48	I	7,8	m	66	<p>hypopharynx: squamous cell carcinoma lymph node: tumor metastasis</p>	<p>1. Hypopharynx, larynx, esophagus, total laryngopharyngoesophagectomy and neck dissection: moderately differentiated squamous cell carcinoma arising from hypopharynx(left pyriform sinus) with</p> <ol style="list-style-type: none"> 1) extension to the submucosal layer of pharynx (but not involve skeletal muscle of the hypopharynx), and adjacent cricoid cartilage 2) presence of perineural invasion 3) esophagus: free of tumor 4) resection margin, superior (pharynx), inferior(esophagus), tracheal and deeper: free of tumor 5) lymph nodes, left level I (0/4), left level II (1/2), left level III (2/8), left level IV (0/16), left level V (0/4), right level II (0/9), right level III (0/14), right level IV (0/12), peripharyngeal (1/2), perithyroidal (0/1) : (4/72) : tumor metastasis in 4 out of 72 lymph nodes without capsular rupture <p>2. Thyroid gland: 1) free of tumor 2) presence of a lobe of parathyroid gland</p> <p>3. Parotid gland: free of tumor</p>	T3N2bM0 (IVA)

A219 : Head and neck cancer tissues

No.	Coordinate		Sex	Age	Key Word	Histological Diagnosis	TNM Stage
49	I	9,10	m	64	<p>hypopharynx: squamous cell carcinoma lymph node: tumor metastasis</p>	<p>Larynx, total laryngectomy: 1) squamous cell carcinoma, moderately differentiated of hypopharynx, with extension to the surrounding strap muscle 2) epiglottis: free of tumor 3) resection margin, proximal: tumor involvement 4) resection margin, distal: free of tumor 5) separately sent: - oropharyngeal lateral wall: tumor involvement - tracheal cartilage: free of tumor - esophageal inlet, left: free of tumor - pyriform sinus, left posterior wall: free of tumor - postcricoid: free of tumor 6) regional lymph nodes (1/108): - tumor involvement in left level II (1/15) - free from the tumor metastasis in left level I (0/3), left level III (0/10), left level IV (0/20), left level V (0/6), right level I (0/1), right level II (0/17), right level III (0/7), right level IV (0/1), right level V (0/11)</p>	T3N1M0 (III)