

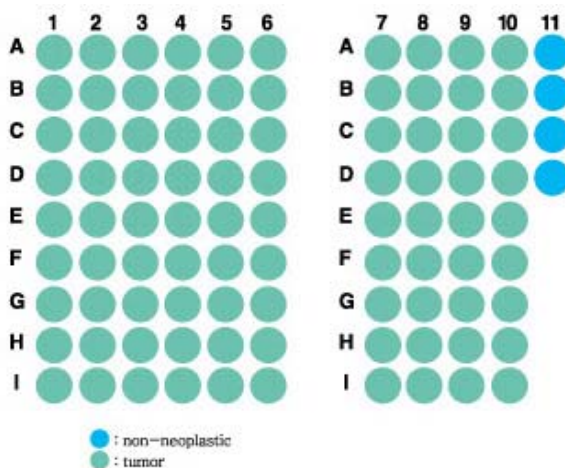
**Specifications:**

- No. of cases: 45
- Tissue type: Larynx cancer tissues
- No. of spots: 2 spots from each cancer case (90 spots)  
4 non-neoplastic spots (4 spots)
- Total spots: 94
- Corresponding normal tissues with cancers: Yes
- Diameter: 1.0 mm

**Documents:**

- Product specification: layout, summary of tissue spots
- H&E stained images
- Detailed pathological information

**Layout:**



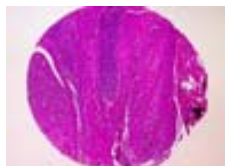
**Summary of tissue spots**

No.	Coordinate	Sex	Age	Key Word	Location	TNM Stage
1	1,2	m	86	squamous cell carcinoma supraglottic	supraglottis	T2N0M0 ( II )
2	3,4	m	69	squamous cell carcinoma undifferentiated carcinoma	supraglottic	T4aN2aM0 ( IVA )
3	5,6	m	83	squamous cell carcinoma epidermoid carcinoma tumor metastasis	supraglottic	T1N1M0 ( III )
4	7,8	m	70	squamous cell carcinoma	supraglottic	T2N1M0 ( III )
5	9,10	m	66	squamous cell carcinoma	glottic	T3N0M0 ( III )
6	11			non-neoplastic from F9, 10		
7	1,2	m	65	squamous cell carcinoma	glottic	T4aN0M0 ( IVA )
8	3,4	m	60	squamous cell carcinoma	supraglottic	T2N1M0 ( III )
9	5,6	m	69	squamous cell carcinoma	supraglottic	T2N1M0 ( III )
10	7,8	m	62	squamous cell carcinoma	glottic	T3N0M0 ( III )
11	9,10	m	59	squamous cell carcinoma	supraglottic	T2N0M0 ( II )
12	11			non-neoplastic from I 1, 2		
13	1,2	m	67	squamous cell carcinoma	transglottic	T4aN1M0 ( IVA )
14	3,4	m	67	squamous cell carcinoma	glottic	T3N0M0 ( III )
15	5,6	m	69	squamous cell carcinoma	transglottic	T4aN2cM0 ( IVA )
16	7,8	m	69	squamous cell carcinoma	supraglottic pyriform sinus	T4aN2aM0 ( IVA )
17	9,10	m	64	squamous cell carcinoma	glottic	T2N0M0 ( II )
18	11			non-neoplastic from I 3, 4		
19	1,2	m	84	squamous cell carcinoma	glottic	T4aN0M0 ( IVA )
20	3,4	m	67	squamous cell carcinoma	supraglottic	T2N2bM0 ( IVA )
21	5,6	m	72	squamous cell carcinoma	glottic	T2N0M0 ( II )
22	7,8	m	38	squamous cell carcinoma invasive squamous cell carcinoma	hypopharynx	T3N2aM0 ( IVA )
23	9,10	m	70	squamous cell carcinoma	transglottic	T4aN0M0 ( IVA )
24	11			non-neoplastic from G9,10		
25	1,2	m	66	squamous cell carcinoma	glottic	T1bN0M0 ( I )
26	3,4	m	69	squamous cell carcinoma	transglottic	T4aN0M0 ( IVA )
27	5,6	m	74	squamous cell carcinoma	supraglottic	T2N1M0 ( III )
28	7,8	m	52	squamous cell carcinoma	glottic	T3N0M0 ( III )
29	9,10	m	72	squamous cell carcinoma	glottic	T2N2bM0 ( IVA )

**Summary of tissue spots**

No.	Coordinate	Sex	Age	Key Word	Location	TNM Stage	
30	F	1,2	f	72	squamous cell carcinoma	supraglottic	T1N2aM0 ( IVA )
31		3,4	f	78	squamous cell carcinoma	supraglottic	T3N0M0 ( III )
32		5,6	m	61	squamous cell carcinoma	supraglottic	T3N1M0 ( III )
33		7,8	m	71	invasive squamous cell carcinoma	pyriform sinus	T3N0M0 ( III )
34		9,10	m	71	invasive squamous cell carcinoma	transglottic	T4aN0M0 ( IVA )
35	G	1,2	m	78	squamous cell carcinoma	transglottic	T3N0M0 ( III )
36		3,4	m	52	squamous cell carcinoma thyroid gland papillary carcinoma	pyriform sinus	T4aN2bM0 ( IVA )
37		5,6	m	77	squamous cell carcinoma	transglottic	T3N1M0 ( III )
38		7,8	m	65	invasive squamous cell carcinoma	transglottic	T4aN1M0 ( IVA )
39		9,10	m	73	invasive squamous cell carcinoma	glottic	T3N0M1 ( IVC )
40	H	1,2	m	73	invasive squamous cell carcinoma	transglottic	T4aN2bM0 ( IVA )
41		3,4	m	57	invasive squamous cell carcinoma	pyriform sinus	T3N2bM0 ( IVA )
42		5,6	m	71	invasive squamous cell carcinoma	supraglottic	T3N2M0 ( IVA )
43		7,8	m	74	invasive squamous cell carcinoma	supraglottic	T4aN0M0 ( IVA )
44		9,10	m	63	squamous cell carcinoma	glottic	T4aN0M0 ( IVA )
45	I	1,2	f	65	invasive squamous cell carcinoma	supraglottic	T2N2M0 ( IVA )
46		3,4	m	62	invasive squamous cell carcinoma	glottic	T3N0M0 ( III )
47		5,6	m	71	invasive squamous cell carcinoma	transglottic	T4aN2bM0 ( IVA )
48		7,8	m	81	squamous cell carcinoma	glottic	T3N0M0 ( III )
49		9,10	m	64	squamous cell carcinoma	glottic	T3N0M0 ( III )

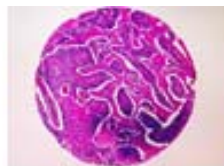**QC sheet\_LOT#122120402031**  
**Hematoxylin and Eosin staining**



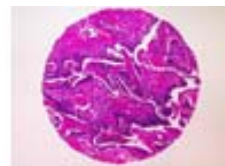
A1



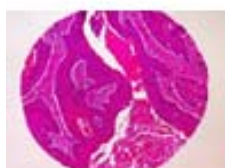A2



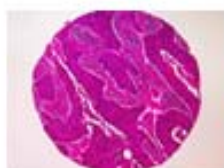A3



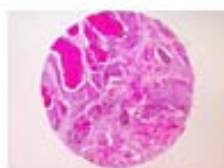
A4



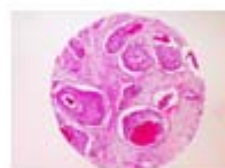A5



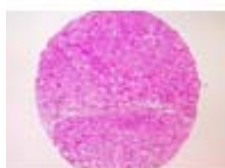A6



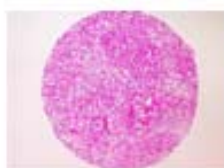A7



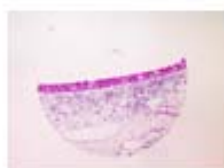A8



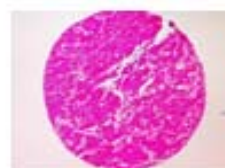A9



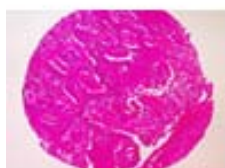A10



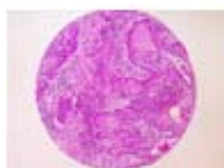A11



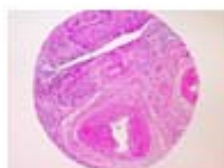B1



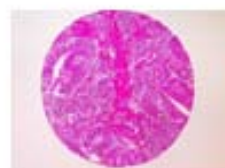B2



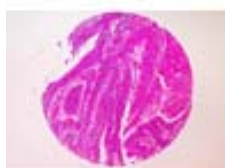B3



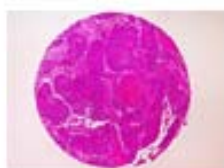B4



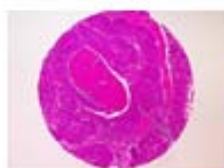B5



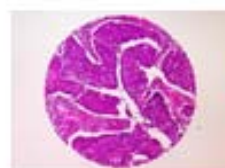B6



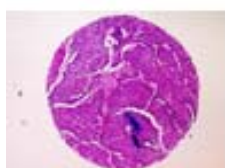
B7



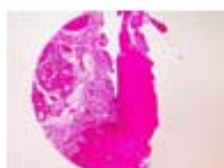
B8



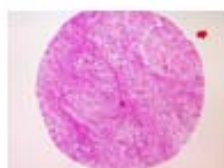B9



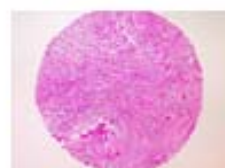B10



B11

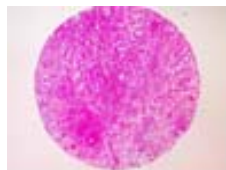

C1

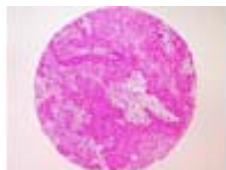

C2

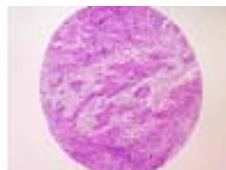**QC sheet\_LOT#122120402031**  
**Hematoxylin and Eosin staining**



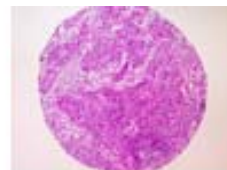C3



C4



C5



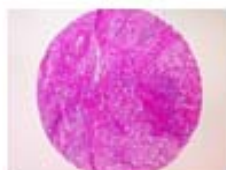C6



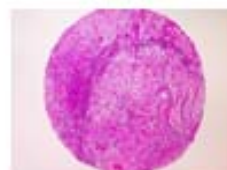C7



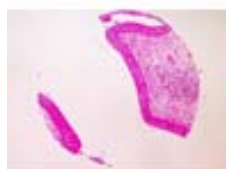
C8



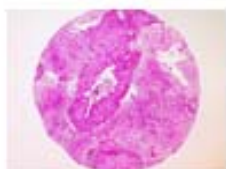
C9



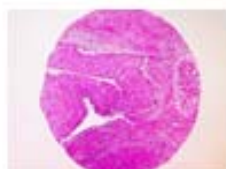C10



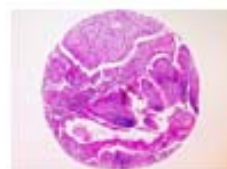
C11



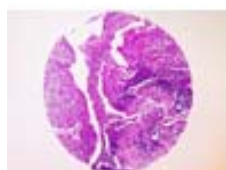
D1



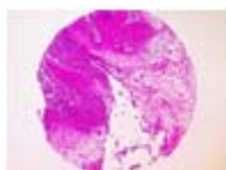
D2



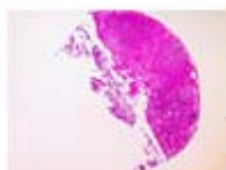D3



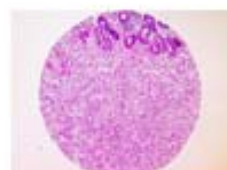
D4



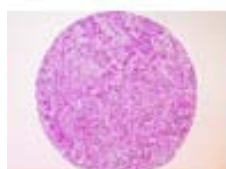D5



D6



D7



D8



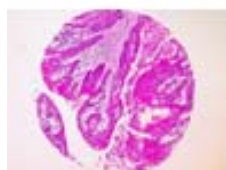D9



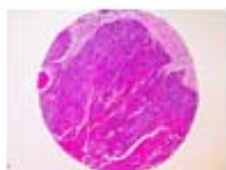
D10



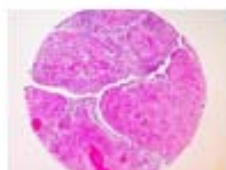
D11



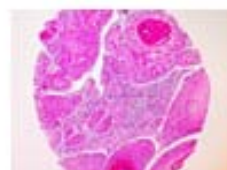E1



E2

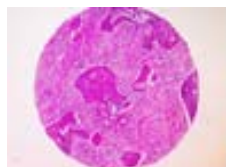


E3

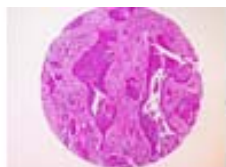


E4

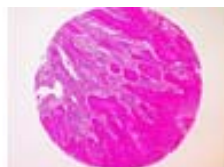**QC sheet\_LOT#122120402031**  
**Hematoxylin and Eosin staining**



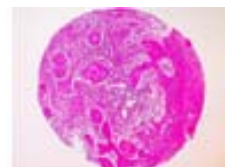
**E5**



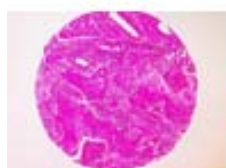**E6**



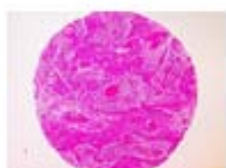**E7**



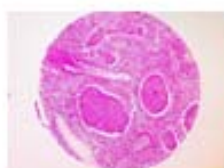
**E8**



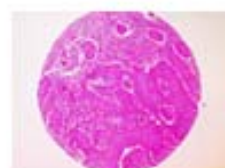
**E9**



**E10**



**F1**



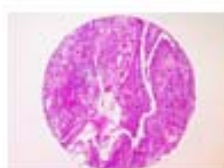**F2**



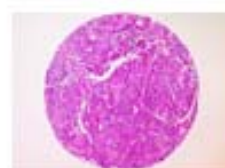
**F3**



**F4**



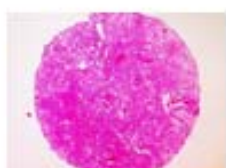**F5**



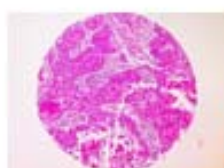
**F6**



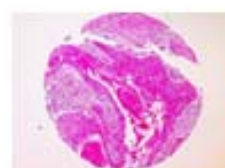
**F7**



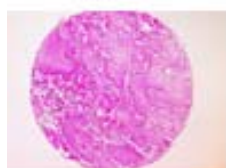**F8**



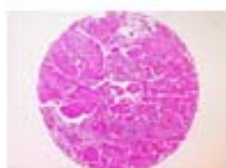
**F9**



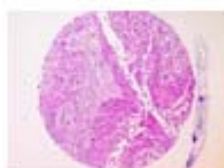
**F10**



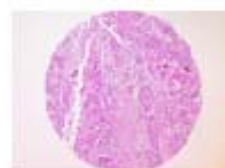**G1**



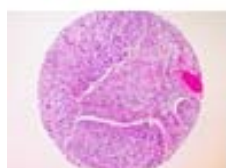**G2**



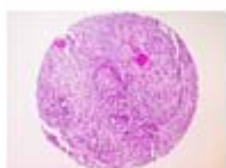
**G3**



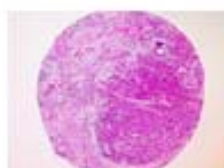**G4**



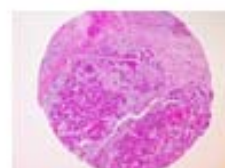
**G5**



**G6**

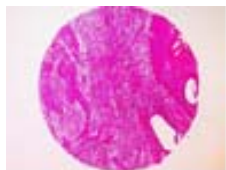

**G7**

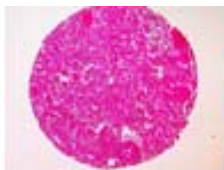

**G8**

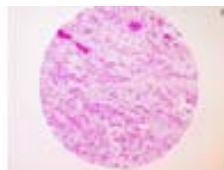
**QC sheet\_LOT#122120402031**  
**Hematoxylin and Eosin staining**



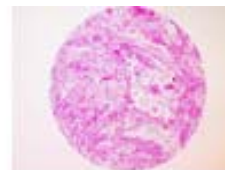
**G9**



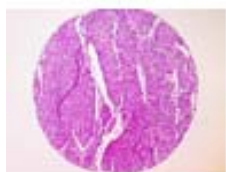
**G10**



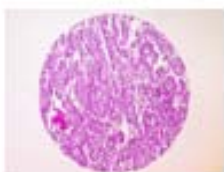
**H1**



**H2**



**H3**



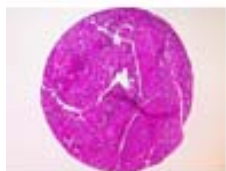**H4**



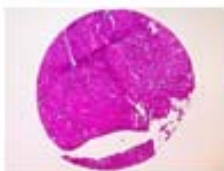**H5**



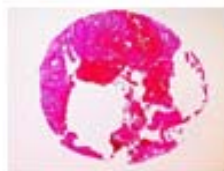**H6**



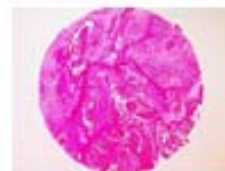**H7**



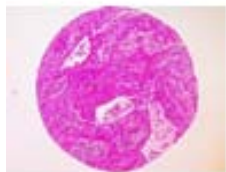**H8**



**H9**



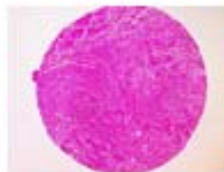**H10**



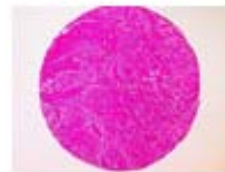**I1**



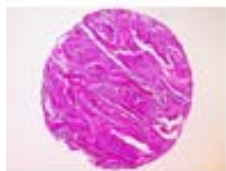**I2**



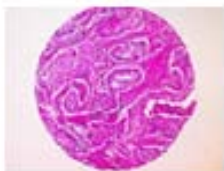**I3**



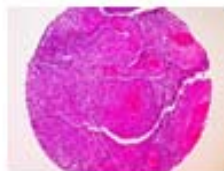
**I4**



**I5**



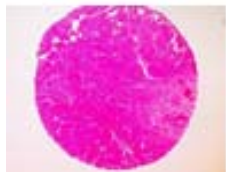**I6**



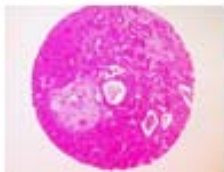
**I7**



**I8**



**I9**



**I10**

**A220 : Larynx cancer tissue**

No.	Coordinate		Sex	Age	Key Word	Histological Diagonosis	Location	TNM Stage
1	A	1,2	m	86	squamous cell carcinoma supraglottic	Larynx and left neck: Invasive, moderately well-differentiated squamous cell carcinoma arising from aryepiglottic fold, with involvement of the adjacent left ventricular fold and base of epiglottis, one of level II lymph nodes showing microscopic focus of metastatic squamous cell carcinoma, none of the level III-V nodes or surgical margins show neoplastic involvement	supraglottis	T2N0M0 ( II )
2	A	3,4	m	69	squamous cell carcinoma undifferentiated carcinoma	Larynx, total laryngectomy: 1) moderately differentiated squamous cell carcinoma mixed with undifferentiated carcinoma, fungating, supraglottic both right and left, involving false cord with involvement of base and laryngeal surface of intrahyoid epiglottis, without extension to thyroid cartilage 2) resection margins, pharyngeal, lingual, and trachea, free of tumor 3) tracheostomy site, acute and chronic nonspecific inflammation without tumor extension 4) lymph node, left, radical neck dissection, level II (0/22), level III (0/13), level IV (0/11), level V (0/44), separately sent level VI (1/3) : (1/93), tumor metastasis in one out of 93 nodes 5) jugular vein, sternocleidomastoid muscle, and submandibular gland, free of tumor 6) lymph node, right, radical neck dissection, level I (0/3), level II (0/3), level III (0/31), level IV (0/48), level V (0/6) : (0/91), free of tumor 7) jugular vein, sternocleidomastoid muscle, free of tumor	supraglottic	T4aN2aM0 ( IVA )
3	A	5,6	m	83	squamous cell carcinoma epidermoid carcinoma tumor metastasis	Larynx and product of neck dissection: 1) larynx, epidermoid carcinoma, moderately differentiated, supraglottic left side, with involvement of false vocal cord and pre-epiglottic space, but preservation of vocal cord 2) resection margin, distal, trachea: free of tumor resection margin, anterior and posterior: free of tumor 3) regional lymph nodes: tumor metastasis to 4 out of 47, followings, N2 (0/5), N3 (1/9), N4 (3/15), N8 (0/11), N11 (0/5), and prethyroidal cartilage (0/2)	supraglottic	T1N1M0 ( III )
4	A	7,8	m	70	squamous cell carcinoma	Larynx, total laryngectomy and neck dissection: fungating squamous cell carcinoma, moderately differentiated, supraglottic, involving left lateral false vocal cord and ventricular space, accrossing the midline to the right with 1) moderate desmoplastic reaction 2) presence of lymphatic permeation 3) associated with in situ lesion 4) marked central tumor necrosis 5) resection margin, superior: involvement of squamous cell carcinoma 6) resection margins, right and left lateral, anterior, posterior and inferior: free of tumor 7) regional lymph nodes, right level I (0/26), right level II (0/21), right level III (0/8), left level I (0/19), left level II (1/5), left level III (0/6): metastatic squamous cell carcinoma in 1 out of 85 nodes	supraglottic	T2N1M0 ( III )

A220 : Larynx cancer tissue

No.	Coordinate		Sex	Age	Key Word	Histological Diagonosis	Location	TNM Stage
5	A	9,10	m	66	squamous cell carcinoma	Larynx, total laryngectomy: squamous cell carcinoma, poorly differentiated 1) involving true and false vocal cord and ventricle of right larynx 2) with marked ulceration and stromal hyalinization 3) without involving thyroid cartilage 4) with occasional lymphatic permeation 5) resection margin, lingual, pharyngeal and tracheal: free of tumor 6) regional lymph node, neck dissection, right level II (0/15), right level III (0/5), right level IV (0/21), left level II (0/4), left level III (0/4), left level IV (0/13) : (0/62): free of tumor	glottic	T3N0M0 ( III )
6	A	11			non-neoplastic	Non-neoplastic from F9, 10		
7	B	1,2	m	65	squamous cell carcinoma	1. Larynx, total laryngectomy: glottic squamous cell carcinoma, moderately differentiated, with invasion through thyroid cartilage and extension to the perilaryngeal soft tissue 1) resection margin, left pyriform sinus, multifocal dysplastic change 2) resection margin, right pyriform sinus and trachea: free of tumor 3) lymph node (0/1): free of tumor metastasis 2. Hyoid bone: free of tumor	glottic	T4aN0M0 ( IVA )
8	B	3,4	m	60	squamous cell carcinoma	1. Larynx, total laryngectomy and left radial neck dissection: supraglottic squamous cell carcinoma, moderately differentiated, invasive, with involving ventricular band, epiglottis below the level of hyoid bone and arytenoid area without invasion to thyroid cartilage 1) resection margin, ligual, pharyngeal, trachea I: free of tumor 2) lymph nodes, labelled as level II (0/2), level II (0/7), level III (0/5), level IV (0/7) : (0/21): free of tumor 2. Submandibular gland: free of tumor	supraglottic	T2N1M0 ( III )
9	B	5,6	m	69	squamous cell carcinoma	Larynx, total laryngectomy and neck dissection: moderately differentiated squamous cell carcinoma, involving base of epiglottis (supraglottic carcinoma) without reaching to the level of cartilage 1) resection margins, superior, right lateral, left lateral, inferior, posterior: free of tumor 2) submandibular gland, right and left: no pathological diagnosis 3) regional lymph node, right level III (0/5), right level IV (0/10), left level II (0/7), left level III (0/1), left level IV (0/7): free of tumor in all 30 nodes Note: The neoplasm is confined to the supraglottic area with extension to the anterior commissure of ventricular folds, without extension to the true vocal cord.	supraglottic	T2N1M0 ( III )

**A220 : Larynx cancer tissue**

No.	Coordinate		Sex	Age	Key Word	Histological Diagonosis	Location	TNM Stage
10	B	7,8	m	62	squamous cell carcinoma	<p>1. Larynx: fungating squamous cell carcinoma, moderately differentiated,            1) size: 2.9x3 cm            2) bilateral anterior wall involvement            3) extension through the thyroid cartilage            4) resection margin, anterior wall: free of tumor, but nearly closed            5) resection margin, lower: nearly closed            6) resection margin, upper: free of tumor            7) regional lymph nodes: free of tumor in all nodes (0/41), in detail, IIa left (0/6), IIb left (0/3), III left (0/9), IV left (0/6), central neck (0/2), IIa right (0/2), IIb right (0/2) III right (0/4), IV right (0/7)</p>	glottic	T3N0M0 ( III )
11	B	9,10	m	59	squamous cell carcinoma	<p>Larynx and epiglottis, supraglottic partial laryngectomy:            fungating squamous cell carcinoma, poorly differentiated,            1) involving larynx (bilaterally) and epiglottis            2) size: 3.3x3 cm            3) invasion depth 1.5 cm, but thyroid cartilage preserved            4) resection margins, superior, inferior, right and left lateral, anterior: free of tumor            5) regional lymph nodes: free of tumor in all nodes (0/53), in detail, right level IIB (0/7), right IIA (0/4), right level III (0/3), right level IV (0/11), left level IIB (0/3), left level IIA (0/8), left level III (0/6), left level IV (0/11)</p>	supraglottic	T2N0M0 ( II )
12	B	11			non-neoplastic	Non-neoplastic from I 1, 2		
13	C	1,2	m	67	squamous cell carcinoma	<p>1. Larynx, total laryngectomy and RND:            squamous cell carcinoma, moderately differentiated, with            1) involvement of supraglottis, and vocal cord, left, with focal extension to the right side (transglottic carcinoma)            2) extension to the thyroid cartilage            3) resection margin, superior, tracheal, both lateral: free of tumor            4) lymph nodes, right level II (0/5), right level III (0/3), right level IV (0/5), left level I (0/3), left level II (0/2), level III (0/8), left level IV (0/20), left level V (1/4) : (1/50): tumor metastasis in 1 out of 50 lymph nodes            2. Salivary gland: free of tumor            3. Soft tissue, stated as infrastoma site: chronic nonsepcific inflammation with fibrosis.            4. Soft tissue, stated as posterior cricoid: chronic nonspecific inflammation</p>	transglottic	T4aN1M0 ( IVA )

**A220 : Larynx cancer tissue**

No.	Coordinate	Sex	Age	Key Word	Histological Diagonosis	Location	TNM Stage	
14	C	3,4	m	67	squamous cell carcinoma	<p>1. Larynx, total laryngectomy with neck dissection:</p> <ol style="list-style-type: none"> <li>1) invasive squamous cell carcinoma moderately differentiated confined to the larynx</li> <li>2) subglottic tumor invades to vocal cord (transglottic) without extension to thyroid cartilage and other tissues beyond larynx (T3)</li> <li>3) post tracheostomy state</li> <li>4) resection margin, superior, inferior, lateral, anterior and posterior: free of tumor</li> <li>5) regional lymph nodes, level II right (0/1), left (0/2), level III right (0/0), left (0/1), level IV right (0/0), left (0/0): tumor (0/4): free of tumor in all 4 lymph nodes</li> </ol> <p>2. Thyroid gland: free of tumor</p> <p>3. Parotid gland: pleomorphic adenoma</p>	glottic	T3N0M0 ( III )
15	C	5,6	m	69	squamous cell carcinoma	<p>1. Larynx, total laryngectomy:</p> <p>squamous cell carcinoma, moderately differentiated, transglottic, extension to thyroid cartilage and extralaryngeal soft tissue (T4)</p> <ol style="list-style-type: none"> <li>1) resection margins, superior and inferior: free of tumor</li> <li>2) lymph nodes, radical neck dissection: right: level II (1/5), level III (0/4), level IV (1/9), level V (0/2), left: level I (0/0), level II (8/8), level III (0/7), level IV (0/0), level V (0/7) : (10/42): metastatic squamous cell carcinoma in 10 out of 42 lymph nodes</li> </ol> <p>2. Salivary gland: free of tumor</p>	transglottic	T4aN2cM0 ( IVA )
16	C	7,8	m	69	squamous cell carcinoma	<p>1. Larynx, total laryngectomy:</p> <p>squamous cell carcinoma, moderately differentiated mainly left supraglottic area with</p> <ol style="list-style-type: none"> <li>1) involvement of bilateral vocal cord</li> <li>2) extension to thyroid cartilage, cervical soft tissue, and left pyriform sinus</li> <li>3) resection margin, lingual, tracheal, lateral: free of tumor, see note</li> <li>4) lymph nodes, right, radical neck dissection, level I (0/3), level II (0/13), level III (0/4) : (0/20): free of tumor</li> <li>5) lymph nodes, left, modified radical neck dissection, level I (0/6), level II (0/19), level III (0/19) : (0/45): free of tumor</li> </ol> <ol style="list-style-type: none"> <li>2. Jugular vein, right: free of tumor</li> <li>3. Thyroid glands, bilateral: free of tumor</li> <li>4. Submandibular glands, bilateral: free of tumor</li> <li>5. Thyrohyoid muscle, left: free of tumor</li> <li>6. Hyoid bone: free of tumor</li> </ol> <p>Note: The pharyngeal resection margin is free of tumor on frozen biopsy. However, the tumor is very close to the left pharyngeal margin of total laryngectomy specimen</p>	supraglottic pyriform sinus	T4aN2aM0 ( IVA )

**A220 : Larynx cancer tissue**

No.	Coordinate		Sex	Age	Key Word	Histological Diagonosis	Location	TNM Stage
17	C	9,10	m	64	squamous cell carcinoma	<p>1. Larynx, laryngectomy: squamous cell carcinoma, well differentiated, involving middle and left side of glottic and subglottic portion, with extension to the perilaryngeal soft tissue (T4)</p> <p>1) resection margins: i ) posterior: intralymphatic permeation of squamous cell carcinoma ii ) superior, antero-superior, inferior, right and left lateral: free of tumor</p> <p>2) regional lymph nodes, parathyroidal (0/2): free of tumor in all 2 nodes</p> <p>2. Thyroid, right, thyroidectomy: free of tumor</p>	glottic	T2N0M0 ( II )
18	C	11			non-neoplastic	Non-neoplastic from I 3, 4		
19	D	1,2	m	84	squamous cell carcinoma	<p>Larynx, total laryngectomy: squamous cell carcinoma, moderately well differentiated extending to thyroid cartilage and strap muscles</p> <p>1) resection margins, lingual, pharyngea and tracheal: free of tumor</p> <p>2) lymph nodes, right, lateral, neck dissection: level II (0/1), level III (0/0), level IV (0/10), paratracheal (0/2): (0/13): free of tumor</p> <p>3) lymph nodes, left, lateral neck dissection: level II (0/0), level III (0/6), level IV (0/9), paratracheal (0/1) : (0/16): free of tumor</p> <p>2. Soft tissue, separately submitted as peristomal tissue: free of tumor</p> <p>3. Thyroid gland, right and isthmus, thyroidectomy: adenomatous hyperplasia without evidence of tumor</p>	glottic	T4aN0M0 ( IVA )
20	D	3,4	m	67	squamous cell carcinoma	<p>1. Total laryngectomy with modified right radical neck dissection and left radical neck dissection: squamous cell carcinoma, moderately differentiated, in supraglottis with</p> <p>1) size: 4x3.5x1.5 cm</p> <p>2) invasion through thyroid cartilage and extension to anterior surrounding soft tissue</p> <p>3) intact resection margins including upper, lower, anterior and posterior</p> <p>4) intact bilateral submandibular salivary glands</p> <p>5) intact left jugular vein</p> <p>6) intact hyoid bone</p> <p>7) metastasis to 2 out of 58 lymph nodes (right level I (0/7), right level II (0/2), right level III (0/0), right level IV (0/0), left level I (0/3), left level II (0/4), left level III and IV (1/9), left superficial cervical (0/4), submandibular gland (0/2), right upper superficial (0/2), No.6 (0/10), and No.7 (1/15))</p> <p>2. Soft tissue, clinically left carotid valve, separately submitted: metastatic squamous cell carcinoma</p>	supraglottic	T2N2bM0 ( IVA )

A220 : Larynx cancer tissue

No.	Coordinate	Sex	Age	Key Word	Histological Diagonosis	Location	TNM Stage
21	D 5,6	m	72	squamous cell carcinoma	Larynx, total laryngectomy: 1) mass: invasive squamous cell carcinoma, moderately differentiated involving true vocal cord and ventricle i ) tumor invasion into the superficial submucosa ii ) tumor involvement of anterior commissure iii) no tumor involvement to the surrounding cartilage 2) false vocal cord: squamous cell carcinoma in situ 3) resection margins, superior (preepiglottis) and inferior, anterior and posterior, right and left: free of tumor 4) pyriform sinus, right and left: free of tumor 5) thyroid gland and strap muscle: free of tumor 6) regional lymph nodes: free of tumor in all nodes (0/79), in detail, right level 2b (0/3), right level 2A (0/8), right level 3 (0/8), right level 4 (0/7), left level 2b (0/10), left level 2A (0/16), left level 3 (0/13), left level 4 (0/14)	glottic	T2N0M0 ( II )
22	D 7,8	m	38	squamous cell carcinoma invasive squamous cell carcinoma	1. Larynx, esophagus and neck soft tissue, radical laryngectomy and neck dissection: invasive squamous cell carcinoma, moderately differentiated, arising from hypopharynx, with penetration of cricoid cartilage and infiltration to the opposite laryngeal mucosa and satellite metastatic nodule formation in the soft tissue on right neck 1) resection margin, under the right neck mass: presence of squamous cell carcinoma 2) resection margins, both pyriform sinuses, tracheal and esophageal: free of tumor 2. Skin, right neck: squamous cell carcinoma limited in platisma muscle without subcutaneous and dermal tumor invasion 3. Lymph nodes, right level I (0/5), II (0/21), III (0/4), IV (0/19), V (0/5), left level I (0/0), II (0/24), III (0/6), IV (1/6), V (0/13) and left paratracheal (0/4): metastasis in 1 out of 107 nodes 4. Submandibular glands, both: free of tumor 5. Esophagus: free of tumor	hypopharynx	T3N2aM0 ( IVA )
23	D 9,10	m	70	squamous cell carcinoma	1. Larynx, total laryngectomy: Squamous cell carcinoma, well differentiated, transglottic with estension to the lamina propria (invasion depth: 0.6cm) and vocalis muscle. 1) resection margins, pharyngeal, lingual, inferior and anterior:free of carcinoma 2) lymph nodes, No.1 (0/3): free of carcinoma 2. Thyroid gland, left: 1) free of carcinoma 2) reactive fibroblastic proliferation in a loose myxoid and inflammatory background	transglottic	T4aN0M0 ( IVA )
24	D 11			non-neoplastic	non-neoplastic from G9,10		
25	E 1,2	m	66	squamous cell carcinoma	Larynx, fronto-lateral laryngectomy: Invasive squamous cell carcinoma, moderately differentiated, without cartilagenous involvement, incompletely excised.	glottic	T1bN0M0 ( I )

**A220 : Larynx cancer tissue**

No.	Coordinate		Sex	Age	Key Word	Histological Diagonosis	Location	TNM Stage
26	E	3,4	m	69	squamous cell carcinoma	Larynx, total laryngectomy: 1) squamous cell carcinoma, well differentiated, fungating i ) transglottic involvement ii ) whole circumference involvement of right and left side larynx iii ) with destruction of thyroid cartilage, but surrounding strap muscle preserved 2) resection margins, superior, inferior, right, left, anterior and posterior: free of tumor 3) resection margins, stoma: free of tumor in right superior and inferior stoma, left superior and inferior stoma 4) regional lymph nodes: free of tumor in all nodes (0/39), right level II (0/6), right level III (0/4), right level IV (0/1), left level II (0/15), left level III (0/8), left level IV (0/5)	transglottic	T4aN0M0 ( IVA )
27	E	5,6	m	74	squamous cell carcinoma	Larynx, supraglottic, partial laryngectomy: polypoid squamous cell carcinoma, moderate differentiated, in supraglottic area, with 1) size: 3x1.5x1.5 cm 2) expanding growth 3) penetration of epiglottic cartilage and invasion to periepiglottic soft tissue 4) epithelial dysplasia, mild to moderate, in mucosa of inferior resection margin 5) vascular invasion 6) intact anterior, posterior and tongue, resection margins 7) surrounding mucosa showing high grade epithelial dysplasia 8) intact bilateral SCM muscle, and salivary glands from tumor 9) metastasis to 5 out of 96 neck lymph nodes (right level I (0/6), right level II (0/16), right level III (1/5), right level IV (0/13), left level I (0/5), left level II (0/8), left level IIa (1/13), level IIb (2/13), left level III (0/10), level IV (0/3), level IV, separately submitted (0/4) 10) hyoid bone: intact from tumor	supraglottic	T2N1M0 ( III )
28	E	7,8	m	52	squamous cell carcinoma	Larynx, thyroid gland, total laryngectomy: squamous cell carcinoma, well differentiated, in right intraglottic area with 1) size: 2.5x1.5x1.2 cm 2) extension to cricoid cartilage (invasion depth: up to 1.2 cm) 3) intact resection margin including upper, lower, anterior and posterior 4) intact surrounding tissue including muscle and thyroid gland 5) no tumor metastasis to regional lymph nodes (0/17) (submucosal (0/11) and tracheal (0/6))	glottic	T3N0M0 ( III )
29	E	9,10	m	72	squamous cell carcinoma	1. Larynx with lymph nodes, neck, bilateral, total laryngectomy and dissection: invasive squamous cell carcinoma, well differentiated, with extension to the submucosa but not to thyroid cartilage 1) resection margins, all: free of tumor 2) lymph nodes, right level I (0/1), IIa (0/5), IIb (3/10), III (5/6), IV (3/3) and left level IIa (2/4), IIb (0/3), III (0/3), IV (0/3): metastasis in 13 out of 38 nodes 2. Salivary gland, stated as right level IIb: free of tumor 3. Soft tissue, stated as right external carotid artery: skeletal muscle without vessel.	glottic	T2N2bM0 ( IVA )

**A220 : Larynx cancer tissue**

No.	Coordinate	Sex	Age	Key Word	Histological Diagonosis	Location	TNM Stage
30	F 1,2	f	72	squamous cell carcinoma	Larynx and regional lymph nodes, subtotal laryngectomy and bilateral neck dissection: squamous cell carcinoma, moderately differentiated in supraglottis (suprahyoid epiglottis) with 1) size:1.8x1.4 cm 2) extension to anterior space of epiglottic cartilage 3) depth of invasion: 5 mm 4) no vascular invasion 5) intact resection margins including anterior, posterior and lower ones 6) metastasis to 1 out of 42 of cervical lymph nodes (level I (0/5), left IIa (0/6), left III (0/2), right (0/6), right II (1/5), right III (0/0), right IV (0/4), and right V (0/8)) 7) intact right salivary gland, jugular vein and sternocleidomastoid muscle from tumor 8) intact hyoid bone from tumor	supraglottic	T1N2aM0 ( IVA )
31	F 3,4	f	78	squamous cell carcinoma	Larynx, total laryngectomy: squamous cell carcinoma, moderately differentiated, supraglottic, involving both supra- and infrahyoid epiglottis, extending into thyroid cartilage, without involving true vocal cords 1) resection margins, tongue base and pharyngeal: mild epithelial atypia 2) resection margin, trachea: free of tumor extension 3) lymph nodes, neck dissection, right level IIA (0/10), right level IIB (1/8), right level III (0/2), right level IV (0/7), left level IIA (1/5), left level IIB (0/9), left level III (4/0), left level IV (0/0) : (2/41): metastatic carcinoma in 2 out of 41 nodes (microscopic presence of tumor cell nests in subcapsular sinus in both two nodes)	supraglottic	T3N0M0 ( III )
32	F 5,6	m	61	squamous cell carcinoma	1. Larynx and regional lymph nodes, partial laryngectomy with neck dissection: polypoid squamous cell carcinoma, invasive, moderately differentiated, in supraglottic area with 1) size: 4x3 cm in two dimension 2) expanding growth 3) extension to epiglottic cartilage 4) no vascular invasion 5) intact anterior, posterior, upper and lower resection margins 6) metastasis to 1 out of 70 regional lymph nodes (left IIB (0/11), left IIA (0/12), left III (0/3), left IV (0/3) right IIB (0/11), right IIA (1/15), right III (0/8), right IV (0/6), and right level IIB (0/1)) 2. Hyoid bone and thyroid cartilage: free from tumor extension	supraglottic	T3N1M0 ( III )
33	F 7,8	m	71	invasive squamous cell carcinoma	Larynx, pharynx, total laryngectomy, partial pharyngectomy, lateral neck node dissection: invasive squamous cell carcinoma, well differentiated, involving right pyriform sinus without infiltration to the cartilage area 1) resection margin, pharyngeal, lingual, tracheal, skeletal muscle and soft tissue: free of tumor 2) regional lymph nodes: right, level II (0/14), III (0/7), IV (0/9): free of tumor left, level II (0/6), III (0/27), IV (0/10): free of tumor	pyriform sinus	T3N0M0 ( III )

**A220 : Larynx cancer tissue**

No.	Coordinate		Sex	Age	Key Word	Histological Diagonosis	Location	TNM Stage
34	F	9,10	m	71	invasive squamous cell carcinoma	<p>1. Larynx, total laryngectomy with radical neck dissection: invasive squamous cell carcinoma, well differentiated involving both sides of vocal cord and penetration of thyroid cartilage and extension to the inner side of skeletal muscle</p> <p>1) resection margins, superior and inferior: free of tumor 2) regional lymph nodes, level 2, right (0/14), left (0/5), level 3, right (0/9), left (0/7), level 4, right (0/8), left (0/2): (0/45): free of tumor in all 45 lymph nodes</p> <p>2. Thyroid gland: free of tumor</p>	transglottic	T4aN0M0 ( IVA )
35	G	1,2	m	78	squamous cell carcinoma	<p>Larynx with regional lymph nodes, total laryngectomy and bilateral neck dissection: polypoid squamous cell carcinoma, moderately differentiated, in glottic, supra-and subglottic, with</p> <p>1) size: 3x2.5x1.5 cm 2) expanding growth 3) extension to thyroid cartilage 4) no vascular invasion 5) intact anterior, posterior, superior and inferior resection margins 6) metastasis to 3 out of 38 regional lymph nodes (right IIb (0/7), right IIa (0/5), right III (0/2), right IV (3/7), left IIb (0/1), left IIa (0/6), left III (0/4), and left IV (0/6)) 7) intact hyoid bone and skeletal muscle anteriorly located from tumor</p>	transglottic	T3N0M0 ( III )
36	G	3,4	m	52	squamous cell carcinoma thyroid gland papillary carcinoma	<p>Larynx, pharynx and left thyroid, total laryngectomy, partial pharyngectomy, left hemithyroidectomy and lateral neck dissection:</p> <p>1) invasive squamous cell carcinoma, moderately differentiated, arising from left pyriform sinus of hypopharynx i ) extension to the vocal cord posteriorly and to the strap muscle anteriorly ii ) extension to the right side pyriform sinus (opposite side)</p> <p>2) resection margin, superior, inferior and left lateral: free of tumor, but closely attached to the mass 3) resection margin, right lateral: free of tumor 4) regional lymph nodes: tumor metastasis to 2 out of 61 (2/61), in detail, right level II (1/13), right level III (1/10), right level IV (0/8), left level II (0/15), left level III (0/3), left level IV (0/12)</p> <p>2. Thyroid gland, left: papillary carcinoma 1) size: 0.4 cm in diameter 2) confined within the parenchyme</p>	pyriform sinus	T4aN2bM0 ( IVA )

**A220 : Larynx cancer tissue**

No.	Coordinate		Sex	Age	Key Word	Histological Diagonosis	Location	TNM Stage
37	G	5,6	m	77	squamous cell carcinoma	<p>Larynx, laryngectomy:</p> <p>1) squamous cell carcinoma, invasive, moderately differentiated,            i ) transglottic involvement and bilateral involvement            ii ) about 6 cm in length            iii) invasion depth: 0.7 cm</p> <p>2) resection margins, superior, inferior, right lateral, left lateral, anterior, and trachea resection: free of tumor</p> <p>3) regional lymph nodes: tumor metastasis to 1 out of 41 (1/41), in detail, right level IIb (0/3), right level IIa (1/4), right level IV (0/5), right level V (0/2), left level IIb (0/7), left level Ia (0/8), left level III (0/3), left level V (0/7), epiglottis (0/0), trachea (0/0), right level III (0/1), left level IV (0/1)</p>	transglottic	T3N1M0 ( III )
38	G	7,8	m	65	invasive squamous cell carcinoma	<p>1. Larynx and attached soft tissue and lymph nodes, total laryngectomy:            invasive squamous cell carcinoma, modeately differentaited, involving both sides of glottic, supra-and sub-glottic area, with penetration of the thyroid cartilage and extension to the extralaryngeal soft tissue including skeletal muscles</p> <p>1) resection margins, right and left pharyngeal, and tracheal: free of tumor</p> <p>2) lymph nodes, right level II (0/1), III (0/6), and IV (0/3), No.5 (1/3),6 (0/0) and 7 (0/3), left level II (0/1), III (0/5) and IV (0/1): metastasis in 1 out of 23 lymph nodes</p> <p>2. Thyroid and parathyroid gland: no pathological diagnosis</p>	transglottic	T4aN1M0 ( IVA )

**A220 : Larynx cancer tissue**

No.	Coordinate		Sex	Age	Key Word	Histological Diagonosis	Location	TNM Stage
39	G	9,10	m	73	invasive squamous cell carcinoma	Larynx, total laryngectomy: invasive squamous cell carcinoma, moderately differentiated, with extension but not penetration to the thyroid cartilage, involving right glottic area 1) resection margin, right pharyngeal: moderate epithelial dysplasia 2) resection margins, left pharyngeal and tracheal: free of tumor	glottic	T3N0M1 ( IVC )
40	H	1,2	m	73	invasive squamous cell carcinoma	1. Larynx: invasive squamous cell carcinoma, well differentiated, involving both sides and supra and infraglottic area and penetration cricoid cartilage and infiltrating to the external capsule of thyroid gland and attached skeletal muscle 1) resection margins, superior inferior and both lateral: free of tumor extension 2) lymph nodes, labelled as I (0/3), II (0/4), III (0/6), IV (2/10) and parotid artery (0/4): metastasis in 2 out of 27 nodes 2. Soft tissue, tracheostomy stoma, abscess with fibrosis	transglottic	T4aN2bM0 ( IVA )
41	H	3,4	m	57	invasive squamous cell carcinoma	Larynx, total laryngectomy: invasive squamous cell carcinoma, moderately differentiated, involving pyriform sinus with 1) no extension to the thyroid cartilage, vocal cord and resection margin of underlying skeletal muscles 2) lymphovascular permeation 3) resection margin, upper, lateral, inferior: free of tumor	pyriform sinus	T3N2bM0 ( IVA )
42	H	5,6	m	71	invasive squamous cell carcinoma	Larynx with lymph nodes, bilateral neck, total laryngectomy with dissection: invasive squamous cell carcinoma, well differentiated, supraglottic with extension to the pyriform sinus and abutting to the thyroid cartilage (T3) 1) tumor size: 3.2x2.5 cm 2) maximal thickness: 2 cm 3) resection margin, pharyngeal: presence of carcinoma in situ with focal lamina propria invasion 4) resection margins, anterior (preepiglottic and soft tissue of neck) and inferior (trachea): free of tumor 5) lymph nodes, left level IIA (0/10), left level IIB (0/1), left level III (3/7), left level IV (0/8), right level IIA (1/6), right level IIB (0/5), right level III (0/10) and right level IV (0/6) : (4/53): metastatic squamous cell carcinoma in 4 out of 53 lymph nodes without perinodal extension (0.6 cm in largest involved node, right level IIA)	supraglottic	T3N2M0 ( IVA )

A220 : Larynx cancer tissue

No.	Coordinate		Sex	Age	Key Word	Histological Diagonosis	Location	TNM Stage
43	H	7,8	m	74	invasive squamous cell carcinoma	<p>1. Larynx, total laryngectomy and neck dissection: invasive squamous cell carcinoma, moderately differentiated, supraglottic, confined to the larynx without extension to the thyroid cartilage</p> <p>1) resection margin, proximal, distal and lateral: free of tumor 2) lymph node, right level II (0/3), level III (0/7), level IV (0/9), level V (0/12), left level II (0/13), level III (0/13), level IV (0/2), level V (0/1): free of tumor</p> <p>2. Thyroid cartilage: free of tumor</p>	supraglottic	T4aN0M0 ( IVA )
44	H	9,10	m	63	squamous cell carcinoma	<p>Larynx, hemilaryngectomy: squamous cell carcinoma, well differentiated, with extension to thyroid cartilage</p>	glottic	T4aN0M0 ( IVA )
45	I	1,2	f	65	invasive squamous cell carcinoma	<p>1. Larynx with lymph nodes, total laryngectomy with bilateral radical neck dissection: invasive squamous cell carcinoma, moderately differentiated, supraglottic, with extension through epiglottic cartilage into the preepiglottic spaces (maximum invasion depth: 9 mm)</p> <p>1) resection margin, superior: extension of carcinoma 2) resection margins, inferior, anterior and posterior: free of tumor 3) regional lymph nodes of neck: metastasis to 2 out of 106 lymph nodes with perinodal soft tissue extension (No.1 (0/4), No.2 (1/15), No.3 (0/8), No.4 (0/14), No.5 (0/30), No.6 (0/13), No.7 (0/11), No.8 (1/8), No.9 (0/3))</p> <p>2. Cystic mass, separately submitted: epidermal cyst 3. Salivary gland: free from tumor extension</p>	supraglottic	T2N2M0 ( IVA )
46	I	3,4	m	62	invasive squamous cell carcinoma	<p>1. Larynx, laryngectomy: invasive squamous cell carcinoma, moderately differentiated, glottic, with extension to the vocalis muscle and cricoid cartilage</p> <p>1) resection margins, anterior, superior, inferior and medial: free of tumor, see note 2. Soft tissue, face, excision: epidermal cyst</p>	glottic	T3N0M0 ( III )
47	I	5,6	m	71	invasive squamous cell carcinoma	<p>1. Larynx, supracricoid partial laryngectomy: invasive squamous cell carcinoma, moderately differentiated, in transglottic area with</p> <p>1) size: 3x2x1.4 cm 2) expanding growth 3) penetration of thyroid cartilage and extension to soft tissue anteriorly presented 4) no vascular invasion 5) intact resection margins including upper, lower, anterior and posterior resection margins, see note 6) metastasis to 3 out of 63 regional lymph nodes (left level I (0/7), left level II (0/6), left level III (2/6), left level IV (1/7), left level V (0/6), right level II (0/4), right level III (0/13), and right level IV (0/14))</p> <p>2. Salivary gland, submandibular, separately submitted: free from tumor extension</p>	transglottic	T4aN2bM0 ( IVA )

**A220 : Larynx cancer tissue**

No.	Coordinate		Sex	Age	Key Word	Histological Diagonosis	Location	TNM Stage
48	I	7,8	m	81	squamous cell carcinoma	<p>Larynx, total laryngectomy:                      squamous cell carcinoma, glottic type, confined to the left true vocal cord                      1) resection margins, right lateral, left lateral, superior, inferior, posterior: free of tumor                      2) regional lymph node, "lateral dissection" (0/2): free of tumor                      Note: The superficial portions of the laryngeal carcinoma is composed of a rather well differentiated squamous cells (I7) while the deeper part of the neoplasm is very poorly differentiated (I8). The tumor does not involve the false vocal cord. It does not cross the anterior commissure. The grossly recognised erosion of the false vocal cord on the opposite side is characterized by laryngeal keratosis with moderate dysplasia, focal erosion and fibrinoid stromal degeneration.</p>	glottic	T3N0M0 ( III )
49	I	9,10	m	64	squamous cell carcinoma	<p>1. Larynx, total laryngectomy:                      squamous cell carcinoma, well differentiated, with arising from left glottic portion and extension to right side, with infiltration around thyroid cartilage but not invasion to cartilage and perilaryngeal soft tissue                      1) resection margin, tracheal: free of tumor                      2) resection margin, left lateral, right lateral, superior and inferior: free of tumor                      3) regional lymph nodes, level II (0/4), level III (0/12), level IV (0/13), level V (0/5) : (0/34): free of tumor                      2. Parotid gland: free of tumor</p>	glottic	T3N0M0 ( III )