

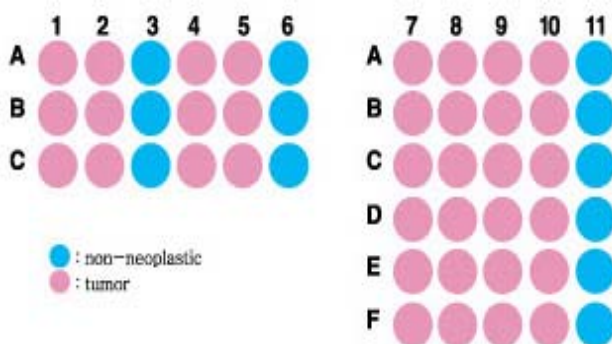
**Specifications:**

- No. of cases: 18
- Tissue type: Various cancer tissues with normal tissues
- No. of spots: 2 spots from each cancer case (36 spots)  
12 non-neoplastic spots (12 spots)
- Total spots: 48
- Corresponding normal tissues with cancers: No
- Diameter: 1.0 mm

**Documents:**

- Product specification: layout, summary of tissue spots
- H&E stained images
- Detailed pathological information

**Layout:**



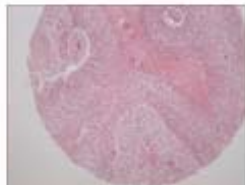
**Summary of tissue spots**

No.	Coordinate	Sex	Age	Tissue Type	Key Word	
1	A	1	M	28	Skin	Squamous cell carcinoma
2		2	M	28	Skin	Squamous cell carcinoma
3		3	F	23	Skin	Non-neoplastic
4		4	F	50	Breast	Ductal carcinoma
5		5	F	50	Breast	Ductal carcinoma
6		6	F	39	Breast	Non-neoplastic
7		7	F	38	Thyroid gland	Papillary carcinoma
8		8	F	38	Thyroid gland	Papillary carcinoma
9		9	F	31	Thyroid gland	Follicular carcinoma
10		10	F	31	Thyroid gland	Follicular carcinoma
11		11	F	36	Thyroid gland	Non-neoplastic
12	B	1	F	57	Kidney	Renal cell carcinoma
13		2	F	57	Kidney	Renal cell carcinoma
14		3	F	66	Kidney	Non-neoplastic
15		4	M	44	Bladder	Transitional cell carcinoma
16		5	M	44	Bladder	Transitional cell carcinoma
17		6	M	44	Bladder	Non-neoplastic
18		7	M	80	Lung	Squamous cell carcinoma
19		8	M	80	Lung	Squamous cell carcinoma
20		9	M	62	Lung	Adenocarcinoma
21		10	M	62	Lung	Adenocarcinoma
22		11	M	68	Lung	Non-neoplastic
23	C	1	M	60	Esophagus	Squamous cell carcinoma
24		2	M	60	Esophagus	Squamous cell carcinoma
25		3	F	67	Esophagus	Non-neoplastic
26		4	M	39	Colon	Adenocarcinoma
27		5	M	39	Colon	Adenocarcinoma
28		6	M	64	Colon	Non-neoplastic
29		7	F	50	Liver	Hepatoma
30		8	F	50	Liver	Hepatoma
31		9	M	64	Liver	Cholagiocarcinoma
32		10	M	64	Liver	Cholagiocarcinoma
33		11	M	64	Liver	Non-neoplastic
34	D	7	F	71	Ovary	Serous carcinoma
35		8	F	71	Ovary	Serous carcinoma
36		9	F	26	Ovary	Mucinous carcinoma
37		10	F	26	Ovary	Mucinous carcinoma
38		11	F	43	Ovary	Non-neoplastic

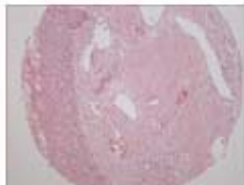
**Summary of tissue spots**

No.	Coordinate	Sex	Age	Tissue Type	Key Word	
39	E	7	F	41	Uterus	Cervix carcinoma
40		8	F	41	Uterus	Cervix carcinoma
41		9	F	45	Uterus	Enometrioid carcinoma
42		10	F	45	Uterus	Enometrioid carcinoma
43		11	F	52	Uterus	Non-neoplastic
44	F	7	F	69	Stomach	Adeno carcinoma
45		8	F	69	Stomach	Adeno carcinoma
46		9	F	67	Stomach	Signetring ring cell carcinoma
47		10	F	67	Stomach	Signetring ring cell carcinoma
48		11	M	64	Stomach	Non-neoplastic

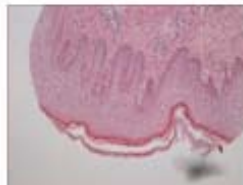
**QC sheet\_LOT# 006021124**  
**Haematoxylin and Eosin staining**



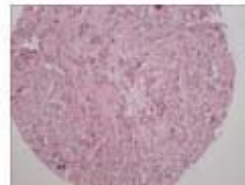
**A1**



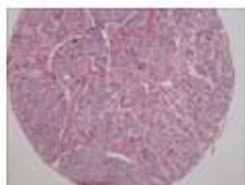
**A2**



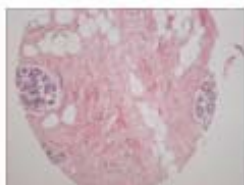
**A3**



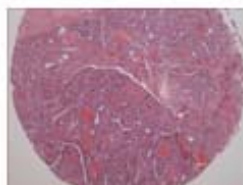
**A4**



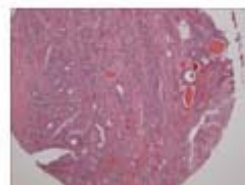
**A5**



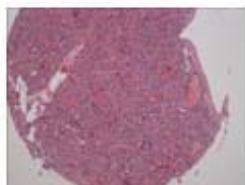
**A6**



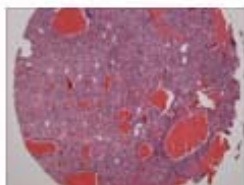
**A7**



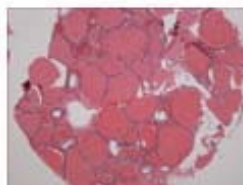
**A8**



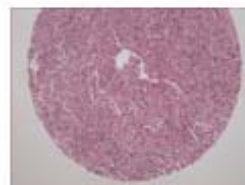
**A9**



**A10**



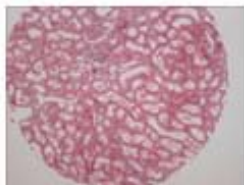
**A11**



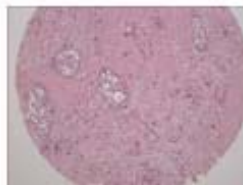
**B1**



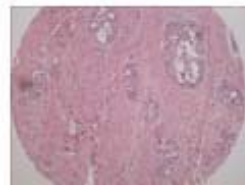
**B2**



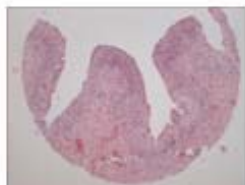**B3**



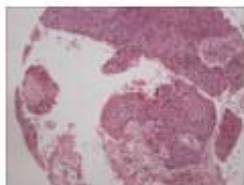
**B4**



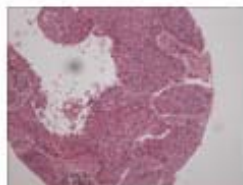
**B5**



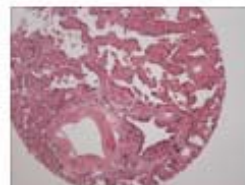
**B6**



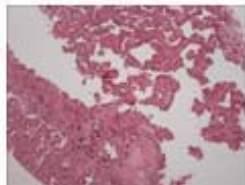
**B7**



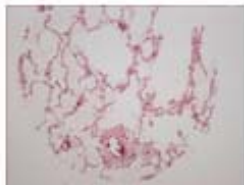**B8**



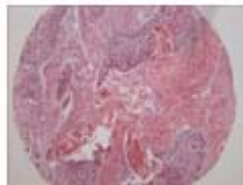
**B9**



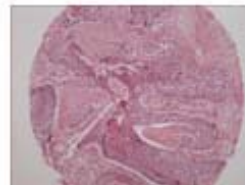
**B10**



**B11**

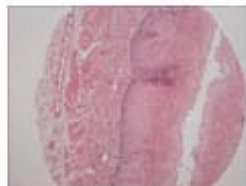

**C1**

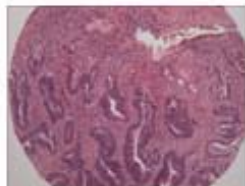


**C2**

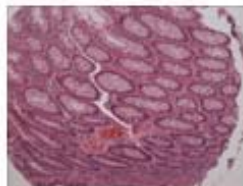**QC sheet\_LOT# 006021124**  
**Haematoxylin and Eosin staining**



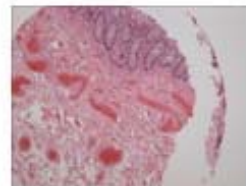
C3



C4



C5



C6



C7



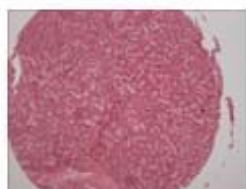
C8



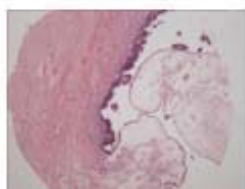
C9



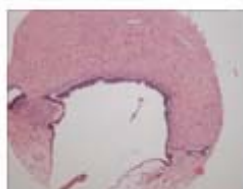C10



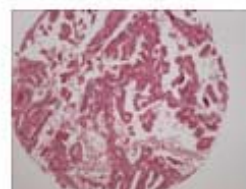
C11



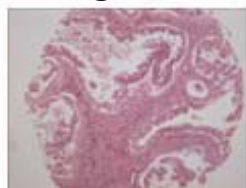D7



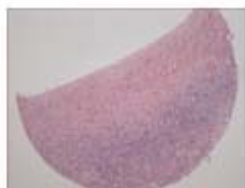D8



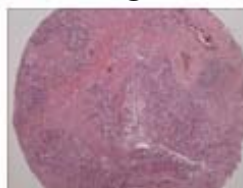D9



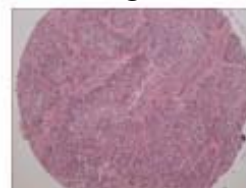D10



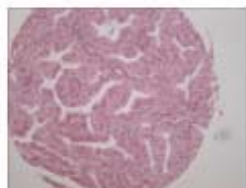
D11



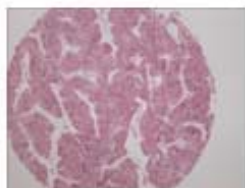
E7



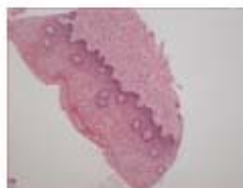E8



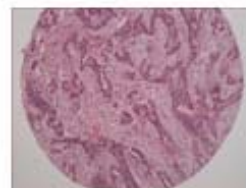
E9



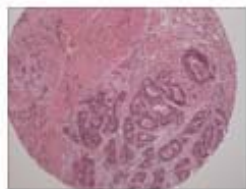
E10



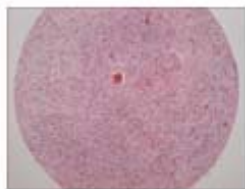
E11



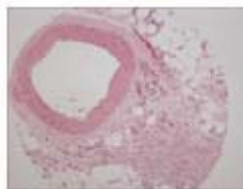
F7



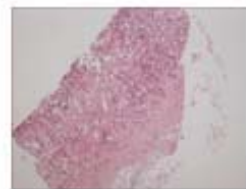
F8



F9



F10



F11

**A301 (I): Various cancer tissues with corresponding normal tissues**

No.	Coordinate		Sex	Age	Key Word	Histological Diagnosis
1	A	1, 2	m	26	skin	1. Skin, scalp, excision: invasive squamous cell carcinoma, well-differentiated 1) extension to the subcutaneous fat tissue (invasion depth: about 3cm ) 2) resection margins, all circumference and base: free of tumor 3) lymph nodes, level 2a (0/36), level 2b (0/11), level III (0/25), level IV (0/13) and level V (0/11) : (0/96): free of tumor
2	A	3	f	21	skin non- neoplastic	1. Soft tissue, axilla, right, excision: lymphangioma
3	A	4, 5	f	48	breast	1. Breast, left, palliative mastectomy: infiltrating ductal carcinoma, with 1) histologic grade: II 2) Black's nuclear grade: I 3) extensive lymphatic invasion 4) intraductal component: less than 10% 5) multinodularity 2. Nipple and areola: free of tumor 3. Overlying skin: superficial dermal invasion by the tumor 4. Underlying fascia: presence of tumor, focal 5. lymph nodes, level I (9/23) and level II (2/2): metastasis in 11 out of 25 lymph nodes (pN1biv) 6. Result of immunohistochemical staining: ER (+), PR (-), C erb B2 (-)
4	A	6	f	37	breast non- neoplastic	1. Breast, right, mastectomy: fibrocystic change with foci of adenosis, 1) columnar cell change and papillomatosis 2) no residual ductal carcinoma in situ 2. Nipple and areola: free of tumor 3. Overlying skin: free of tumor 4. Underlying fascia: free of tumor 1) regional lymph node, axillary (0/8): free of tumor

**A301 (I): Various cancer tissues with corresponding normal tissues**

No.	Coordinate		Sex	Age	Key Word	Histological Diagnosis
5	A	7, 8	f	36	thyroid gland	<p>1. Thyroid, total thyroidectomy: papillary carcinoma 1) size: 4.5x3x2.5 cm 2) extensive extension to perithyroidal soft tissue and surrounding skeletal muscle 3) lymphovascular invasion 4) multiple metastasis to surrounding soft tissue and lymph nodes (29/62: level 2, 3, 4, 5 (12/35), level 2 (2/10), No.6 (1/1), perithyroidal (14/16)) 5) intact jugular vein 6) nodular goiter</p>
6	A	9, 10	f	29	thyroid gland	<p>1. Thyroid gland, right, thyroidectomy: follicular carcinoma, minimally invasive, showing capsular invasion</p>
7	A	11	f	34	thyroid gland non-neoplastic	<p>1. Thyroid gland, thyroidectomy: adenomatous hyperplasia * Note: a parathyroid gland is included.</p>
8	B	1, 2	f	55	kidney	<p>1. Kidney, left, radical nephrectomy: renal cell carcinoma, conventional (clear cell) type 1) Fuhrman's nuclear grade: 4 2) foci of sarcomatoid differentiation 3) Invasion to the perinephric fat tissue but not to Gerota's fascia 4) renal vein involvement (pT3b) 5) resection margin, ureter: free of tumor 6) resection margin, renal vein: Presence of tumor 7) lymph nodes, perihilar (0/11), paraaortic (0/2) and left common iliac (0/3) : free of tumor metastasis in all 16 nodes 2. Adrenal gland: free of tumor</p>

**A301 (I): Various cancer tissues with corresponding normal tissues**

No.	Coordinate		Sex	Age	Key Word	Histological Diagnosis
9	B	3	f	64	kidney non-neoplastic	1. Kidney, right, nephrectomy: angiomyolipoma, focally extending beyond renal capsule, but confined to Gerota's fascia 2. Ureter, resection margin: free of tumor 3. Renal artery and vein: free of tumor 4. Adrenal gland: free of tumor * Result of immunohistochemistry: Vimentin (+), Actin (+), Desmin (+), Low MW Cytokeratin (-), EMA (-), Factor VIII (-), CD31 (-), S-100 (-)
10	B	4, 5	m	22	bladder	1. Urinary bladder including prostate, seminal vesicle and ureter, radical cystectomy: papillary urothelial carcinoma, high grade, with 1) squamous differentiation 2) various pathologic state including low grade papillary urothelial carcinoma 3) urothelial tumor of low malignant potential, carcinoma in situ and papilloma, with 4) extension to the perivesical soft tissue and prostate, and with 5) extensive lymphatic, venous and perineural invasion, incompletely excised 2. Seminal vesicle: free of tumor 3. Ureters, bilateral, resection margins: free of tumor
11	B	6	m	22	bladder	Non-neoplast region from, B 4,5

**A301 (I): Various cancer tissues with corresponding normal tissues**

No.	Coordinate		Sex	Age	Key Word	Histological Diagnosis
12	B	7, 8	m	78	lung	<p>1. Lung, left lower lobe, lobectomy: squamous cell carcinoma, moderately differentiated, 1) size: 6.5x4.5 cm 2) confined within the lung parenchyme 3) presence of tumor emboli.</p> <p>2. Surrounding lung 1) emphysema 2) pulmonary hypertension 3) bronchiolitis with obstructive pneumonia 4) focal septal thickening with fibrosis 5) anthracotic macules and nodules</p> <p>3. Bronchial resection margin: free of tumor 1) regional lymph nodes: free of tumor in all nodes (0/35), in detail, peribronchial (0/5), IPL (0/1), subcarinal (0/10), right hilar (0/5), A-P window (0/9), left hilar (0/5)</p>
13	B	9, 10	m	60	lung	<p>1. Lung, right upper and mid lobes, lobectomy: upper lobe: adenocarcinoma, acinar type, moderately differentiated, mixed 1) papillary carcinoma and bronchioloalveolar carcinoma, 2) extension to the visceral pleura 3) tumor size: 4.5x2.5 cm 4) associated anthracotic nodule with fibrosis 5) bronchial resection margin: free of tumor</p> <p>2. Mid lobe: papillary carcinoma, 1) confined within the lung 2) tumor size: 1.5x0.6 cm 3) bronchial resection margin: free of tumor 4) regional lymph nodes: free of tumor in all nodes (0/12), in detail, IPL (0/3), hilar (0/7), regional (0/2)</p>

**A301 (I): Various cancer tissues with corresponding normal tissues**

No.	Coordinate		Sex	Age	Key Word	Histological Diagnosis
14	B	11	m	66	lung non-neoplastic	<p>1. Lung, right, pneumonectomy: upper lobe: squamous cell carcinoma, moderately differentiated, 1) extension to the visceral pleura 2) marked central necrosis 3) tumor size: 6.3x5.5 cm 4) obstructive pneumonitis in the remaining lung</p> <p>2. Lower lobe: lobar pneumonia 1) resection margin: free of tumor 2) regional lymph nodes: free of tumor in all nodes (0/13), in detail, subcarinal (0/6), lower paratracheal (0/2), regional (0/5)</p>
15	C	1, 2	m	58	esophagus	<p>1. Esophagus, lower, esophagectomy: ulcerative squamous cell carcinoma, moderately differentiated 1) extension to the periesophageal fat tissue 2) lateral margin: free of tumor 3) lymphovascular permeation: positive 4) resection margin, proximal, esophageal: free of tumor 5) resection margin, distal, gastric: free of tumor 6) regional lymph nodes: tumor metastasis to 3 out of 10 (3/10), in detail, gastric node (0/1), paraesophageal (0/6), celiac(3/3)</p>
16	C	3	f	65	esophagus non-neoplastic	<p>1. Stomach with omentum, subtotal gastrectomy: ulcerative adenocarcinoma (Borrmann type II), 1) moderate differentiated, in antrum and pylorus 2) size: 3.8x3.5 cm 3) gastric type (by Japanese classification) and expanding growth (by Ming classification) 4) extension to serosa and perigastric soft tissue 5) vascular invasion 6) intact proximal and distal resection margin 7) no metastasis to omental lymph nodes (0/24: No.3 (0/5), No.4 (0/10), No.8 (0/9) )</p> <p>2. Cystic structure, liver, resection: solitary unilocular cyst</p>

**A301 (I): Various cancer tissues with corresponding normal tissues**

No.	Coordinate		Sex	Age	Key Word	Histological Diagnosis
17	C	4, 5	m	37	colon	<p>1. Sigmoid colon, segmental resection: fungating adenocarcinoma, moderately differentiated, 1) size: 1.7x1.3 cm 2) expanding growth 3) involvement at submucosal space and extension to inner muscle layer 4) no lymphovascular and perineural invasion 5) intact resection margin 6) no metastasis to pericolic lymph nodes (pericolic (0/2) and principal, separately submitted (0/0))</p>
18	C	6	m	62	colon non-neoplastic	<p>1. Stomach, radical proximal gastrectomy: gastrointestinal stromal tumor, malignant, in posterior body 1) size: 14x11x9 cm 2) mitotic count: about 5/10 HPF 3) high cellularity but not significant pleomorphism 4) expanding growth but invasion to mucosa, perigastric fatty tissue and serosa 5) extensive necrosis 6) intact proximal and distal resection margin 7) no omental lymph node metastasis (0/23) : No.1 (0/0), No.2 (0/2, No.3 (0/6), No.4 (0/8), No.7 (0/5), No.8 (0/2), No.11 (0/0) and No.15 (0/0) )</p>
19	C	7, 8	f	48	liver	<p>1. Liver, right, trisegmentectomy: hepatocellular carcinoma, probably arising in liver cell adenoma 1) size: 17x15x10.5 cm 2) single nodular type with perinodal growth (expanding growth) 3) edmondson grade I to II 4) trabecular (majority) and adenoid histologic pattern 5) necrosis: less than 10% of total volume 6) capsular involvement 7) intact resection margin (safety margin: 0.3cm) 8) no vascular invasion 9) nonneoplastic liver showing marked cholestasis with focal biliary cirrhosis and sinusoidal congestion due to mass 2. Gallbladder: cholelithiasis with tumor extension</p>

**A301 (I): Various cancer tissues with corresponding normal tissues**

No.	Coordinate		Sex	Age	Key Word	Histological Diagnosis
20	C	9,10	m	62	liver	1. Liver, right lobe, lobectomy: cholangiocarcinoma, moderately differentiated, peripheral type 1) size: 11.5x9.5x7.0 cm 2) expanding growth and extensive necrosis 3) penetration of hepatic capsule and invasion to soft tissue adjacent to diaphragm 4) vascular invasion (but not portal vein) 5) intrahepatic metastasis 6) intact intrahepatic resection margin and diaphragm 7) nonneoplastic liver showing reactive hepatitis 2. Gallbladder, cholecystectomy: free from tumor extension
21	C	11	m	62	liver	Non-neoplast region from, C 9, 10
22	D	7,8	f	79	ovary	1. Ovary, left, oophorectomy: papillary serous cystadenocarcinoma, 1) grade I 2) showing focally stromal invasion 3) confined within the ovary
23	D	9, 10	f	24	ovary	1. Ovary and fallopian tube, left, salpingoophorectomy: mucinous cystadenocarcinoma 1) confined within the capsule 2. Fallopian tube: free of tumor 3. Ovary, right, partial oophorectomy: mesothelial hyperplasia without tumor 4. Soft tissue, right and left, paracolic gutter, right retroperitoneum: chronic nonspecific inflammation without tumor 5. Omentum, partial omentectomy: chroni nonspecific inflammation with mesothelial hyperplasia
24	D	11	f	41	ovary non- neoplastic	1. Ovary and fallopian tube, left salpingectomy: thecofibroma 2. Fallopian tube: no pathological diagnosis

**A301 (I): Various cancer tissues with corresponding normal tissues**

No.	Coordinate		Sex	Age	Key Word	Histological Diagnosis
25	E	7, 8	f	39	uterus	1. Uterus, radical abdominal hysterectomy: 2. Cervix: invasive squamous cell carcinoma, large cell, keratinizing type (depth of invasion, 11/22mm) with lymphatic invasion 3. Endometrium: secretory phase 4. Myometrium: leiomyoma, intramural 5. Parametria, both: free of tumor 1) lymph nodes, right pelvic (0/10) and left pelvic (0/5): free of tumor metastasis in all 5 nodes
26	E	9, 10	f	43	uterus	1. Uterus, radical abdominal hysterectomy with bilateral salpingo-oophorectomy: 2. Cervix: 1) chronic nonspecific inflammation 2) endometriosis 3. Endometrium: endometrioid carcinoma, well differentiated (grade I), type I 1) superficial myometrial invasion (depth of invasion: 1/20 mm) 2) no lymphatic invasion, and no cervical involvement 3) leiomyomas, intramural 4. Ovaries, bilateral: no pathological diagnosis 5. Fallopian tubes, bilateral: no pathological diagnosis 6. Parametria, bilateral: free of tumor 7. Vaginal cuff: free of tumor 1) lymph nodes, right pelvic (0/8) and left pelvic (0/5): free of tumor metastasis in all 13 nodes
27	E	11	f	50	uterus non-neoplastic	1. Uterus with both adnexae, total abdominal hysterectomy with 1) bilateral salpingo-oophorectomy: 2. Cervix: chronic nonspecific inflammation 3. Endometrium: proliferative phase 4. Myometrium: leiomyoma, intramural 5. Ovaries, both: corpus luteal cyst 6. Fallopian tubes, both: no pathological diagnosis

**A301 (I): Various cancer tissues with corresponding normal tissues**

No.	Coordinate		Sex	Age	Key Word	Histological Diagnosis
28	F	7, 8	f	67	stomach	<p>1. Stomach, subtotal gastrectomy: adenocarcinoma, poorly differentiated, 1) partly signet ring cell carcinoma ulcerative type 2) extension to the perigastric 3) fat tissue and multifocal lymphovascular permeation 4) resection margins, proximal and distal: free of tumor 4) lymph nodes, No.3 (5/6), No.4 (2/6), No.6 (2/8), No.7 (2/8) and No.8 (0/3) : (11/31): tumor metastasis to 11 out of 31 lymph nodes with perinodal soft tissue extension in No.3, No.4 lymph nodes</p>
29	F	9, 10	f	65	stomach	<p>1. Stomach, subtotal gastrectomy: diffuse infiltrative adenocarcinoma (Borrmann type IV), signet ring cell type, in antrum and body 1) size: 5.5x5 cm 2) diffuse type (by Lauren classification) and infiltrative growth (by Ming classification) 3) extension to outer muscle layer. 4) perineural invasion 5) intact proximal and distal resection margins 6) metastasis to 3 out of 36 omental nodes (No.3 (0/2), No.4 (1/6), No.6 (2/9), No.7 (0/13), No.8 (0/4), No.9(0/2) ) 2.Gallbladder, cholecystectomy: free from tumor extension</p>
30	F	11	m	62	stomach non- neoplastic	<p>1. Stomach, radical proximal gastrectomy: gastrointestinal stromal tumor, malignant, in posterior body 1) size: 14x11x9 cm 2) mitotic count: about 5/10 HPF 3) high cellularity but not significant pleomorphism 4) expanding growth but invasion to mucosa, perigastric fatt tissue and serosa 5) extensive necrosis 6) intact proximal and distal resection margin 7) no omental lymph node metastasis (0/23) : No.1 (0/0), No.2 (0/2), No.3 (0/6), No.4 (0/8), No.7 (0/5), No.8 (0/2), No.11 (0/0) and No.15 (0/0) )</p>