

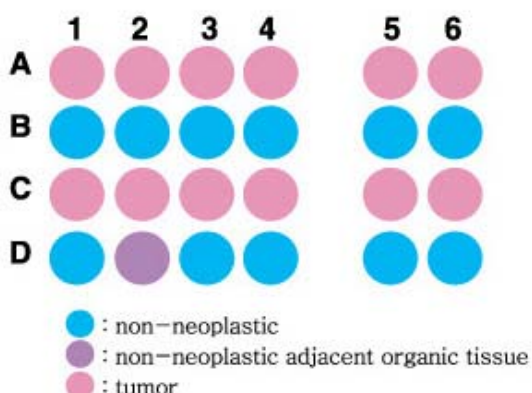
**Specifications:**

- No. of cases: 12
- Tissue type: Test slide, various cancer tissues with corresponding normal tissues
- No. of spots: 1 spot from each cancer case (12 spots)  
12 non-neoplastic spots (12 spots)
- Total spots: 24
- Corresponding normal tissues with cancers: Yes
- Diameter: 1.0 mm

**Documents:**

- Product specification: layout, summary of tissue spots
- H&E stained images
- Detailed pathological information

**Layout:**

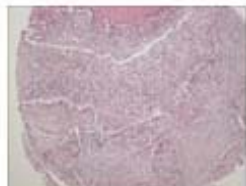

## Summary of tissue spots

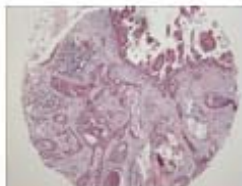
No.	Coordinate	Sex	Age	Specimen	Key Word
1	A1 B1*	m	29	skin	invasive squamous cell carcinoma
2	A2 B2*	f	48	breast	infiltrating ductal carcinoma
3	A3 B3*	f	32	thyroid	follicular carcinoma
4	A4 B4*	m	69	lung	1.squamous cell carcinoma 2.obstructive pneumonitis 3.pneumonia
5	A5 B5*	f	29	liver	hepatocellular carcinoma
6	A6 B6*	f	58	kidney	renal cell carcinoma
7	C1 D1*	m	45	bladder	urothelial carcinoma
8	C2 D2*	f	34	ovary	serous tumor borderline malignancy
9	C3 D3*	f	33	uterus (cervix)	invasive squamous cell carcinoma
10	C4 D4*	m	64	esophagus	basaloid carcinoma
11	C5 D5*	m	67	stomach	signet ring cell carcinoma
12	C6 D6*	m	70	colon	adenocarcinoma

\*: corresponding non-neoplastic tissues

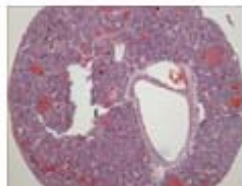
**QC sheet\_LOT#131010304191**  
**Haematoxylin and Eosin staining**



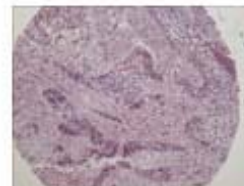A1



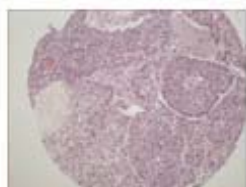
A2



A3



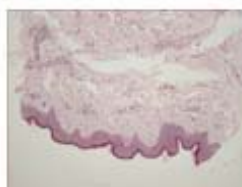A4



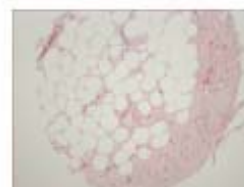
A5



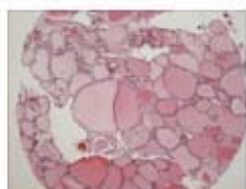
A6



B1



B2



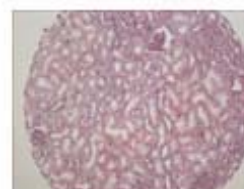B3



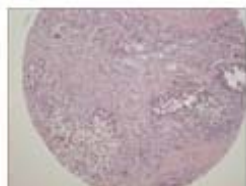B4



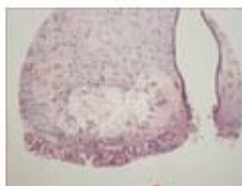B5



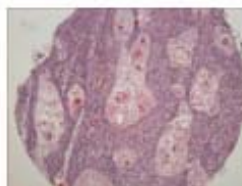
B6



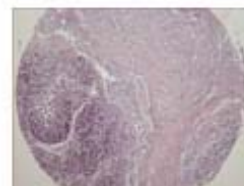
C1



C2



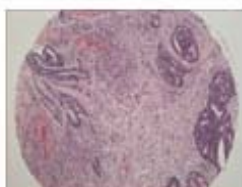C3



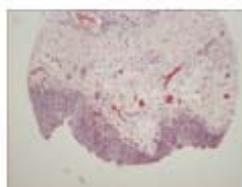
C4



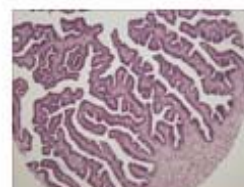C5



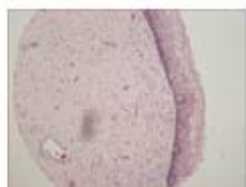C6



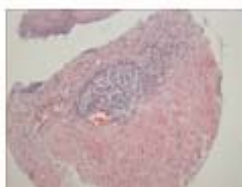
D1



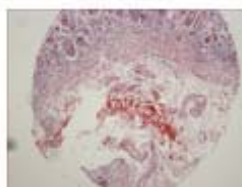
D2



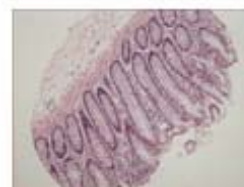D3



D4



D5



D6

**A701: Test slide - Various cancer tissues with corresponding normal tissues**

No.	Coordinate	Sex	Age	Specimen	Key Word	Histological Diagnosis
1	A1 B1*	m	29	skin	invasive squamous cell carcinoma	<p>Skin, scalp, excision:</p> <ol style="list-style-type: none"> <li>1. Invasive squamous cell carcinoma, well-differentiated with extension to the subcutaneous fat tissue (invasion depth: about 3 cm)</li> <li>2. Resection margins, all circumference and base: free of tumor</li> <li>3. Lymph nodes, level 2a (0/36), level 2b (0/11), level III (0/25), level IV (0/13) and level V (0/11) : (0/96): free of tumor</li> </ol>
2	A2 B2*	f	48	breast	infiltrating ductal carcinoma	<p>Breast, right, modified radical mastectomy:</p> <ol style="list-style-type: none"> <li>1. Infiltrating ductal carcinoma               <ol style="list-style-type: none"> <li>1) black's nuclear grade 1 (poorly differentiated)</li> <li>2) modified Bloom and Richardson's histological grade III (tubule formation: 3, nuclear pleomorphism: 3, mitosis: 2)</li> <li>3) no vascular invasion</li> </ol> </li> <li>2. Regional lymph node, axillary (0/18), level III (0/5): (0/23): free of tumor</li> </ol> <p>Note: ER(+), PR(+), C erb B2(-).</p>
3	A3 B3*	f	32	thyroid	follicular carcinoma	<p>Thyroid gland, right, thyroidectomy:</p> <p>follicular carcinoma, minimally invasive, showing capsular invasion</p>
4	A4 B4*	m	69	lung	<ol style="list-style-type: none"> <li>1. squamous cell carcinoma</li> <li>2. obstructive pneumonitis</li> <li>3. pneumonia</li> </ol>	<p>Lung, right, pneumonectomy:</p> <ol style="list-style-type: none"> <li>1. Upper lobe: squamous cell carcinoma, moderately differentiated, with - extension to the visceral pleura               <ul style="list-style-type: none"> <li>- marked central necrosis</li> <li>- tumor size: 6.3x5.5 cm</li> <li>- obstructive pneumonitis in the remaining lung</li> </ul> </li> <li>2. Regional lymph nodes: free of tumor in all nodes (0/13), in detail, subcarinal (0/6), lower paratracheal (0/2), regional (0/5)</li> </ol>

**A701: Test slide - Various cancer tissues with corresponding normal tissues**

No.	Coordinate	Sex	Age	Specimen	Key Word	Histological Diagnosis
5	A5 B5*	f	29	liver	hepatocellular carcinoma	Liver, right, lobectomy: hepatocellular carcinoma, with 1) size: 8x7.6x7.5 cm 2) Edmondson grade II 3) macrotrabecular and pseudoglandular types 4) infiltrative type 5) capsular invasion 6) necrosis: less than 5% of total volume 7) portal vein invasion 8) intact hepatic resection margin 9) non-neoplastic liver showing congestion
6	A6 B6*	f	58	kidney	renal cell carcinoma	Kidney, left, radical nephrectomy: 1. Renal cell carcinoma, conventional (clear cell) type, with 1) Fuhrman's nuclear grade: 4 2) foci of sarcomatoid differentiation 3) invasion to the perinephric fat tissue but not to Gerota's fascia 4) renal vein involvement (pT3b) 2. Lymph nodes, perihilar (0/11), paraaortic (0/2) and left common iliac (0/3): free of tumor metastasis in all 16 nodes
7	C1 D1*	m	45	bladder	urothelial carcinoma	Urinary bladder including prostate, seminal vesicle and ureter, radical cystectomy: Urinary bladder: papillary urothelial carcinoma, high grade, with squamous differentiation, with various pathologic state including low grade papillary urothelial carcinoma, urothelial tumor of low malignant potential, carcinoma in situ and papilloma, with extension to the perivesical soft tissue and prostate, and with extensive lymphatic, venous and perineural invasion, incompletely excised.
8	C2 D2*	f	34	ovary	serous tumor borderline malignancy	Ovary and fallopian tube, side unstated, salpingoophorectomy: Ovary: borderline serous and mucinous tumor with serous micropapillary pattern (so called micropapillary serous adenocarcinoma by Kurman), confined within ovarian capsule. The matched normal tissue of this case is fallopian tube, not ovary.

**A701: Test slide - Various cancer tissues with corresponding normal tissues**

No.	Coordinate	Sex	Age	Specimen	Key Word	Histological Diagnosis
9	C3 D3*	f	33	uterus (cervix)	invasive squamous cell carcinoma	Cervix: invasive squamous cell carcinoma, large cell, keratinizing (invasion depth: 1.1 cm) with focal lymphovascular permeation
10	C4 D4*	m	64	esophagus	basaloid carcinoma	Esophagus, esophagectomy: basaloid squamous cell carcinoma with 1) size: 2.7x2.0x2.0 cm 2) expanding growth 3) involvement at submucosal space and extension to upper border of proper muscle layer 4) intact proximal and distal resection margin 5) no tumor metastasis to upper paraesophageal lymph node (separately submitted:
11	C5 D5*	m	67	stomach	signet ring cell carcinoma	Stomach, subtotal gastrectomy: 1. Signet ring cell carcinoma 1. diffuse infiltrative type 2. with extension to serosa and perigastric fat tissue(SE) 3. frequent lymphatic permeation and perineural invasion 4. focally mixed with tubular adenocarcinoma, moderately differentiated 5. mixed type by Lauren's classification and infiltrative type by Ming's classification 2. Regional lymph nodes, No.3 (6/5), No.4 (1/1), No.5 (0/0), No.6 (9/14), No.7 (1/9), No.8 (0/3), No.12 (0/1), No.13 (0/3), No.17 (0/2) : (17/38): tumor metastasis in 17 out of 38 nodes
12	C6 D6*	m	70	colon	adenocarcinoma	1.Sigmoid colon, radial sigmoid colectomy: A. Adenocarcinoma, poorly differentiated, ulceroinfiltrative type with extension to pericolic fat tissue and is very close to lateral margin (about 0.5 mm) B. Tubular adenoma with high grade dysplasia Resection margins, proximal and distal: free of tumor 2. Regional lymph nodes, principal (0/7), pericolic (2/22) : (2/29): tumor metastasis in 2 out of 29 lymph nodes

\*: corresponding non-neoplastic tissues