

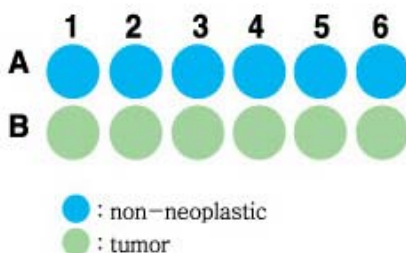
Specifications:

- No. of cases: 6
- Tissue type: Test slide, colon cancer tissues with corresponding normal tissues
- No. of spots: 1 spot from each cancer case (6 spots)
6 non-neoplastic spots (6 spots)
- Total spots: 12
- Corresponding normal tissues with cancers: Yes
- Diameter: 1.0 mm

Documents:

- Product specification: layout, summary of tissue spots
- H&E stained images
- Detailed pathological information

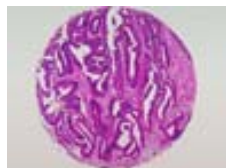Layout:



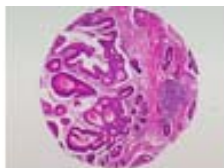
Summary of tissue spots

No.	Coordinate	Sex	Age	Organ	Key Word
1	A1	M	76	colon	Adenocarcinoma
2	B1	M	76	colon	Non-neoplastic from A1
3	A2	F	75	colon	Adenocarcinoma
4	B2	F	75	colon	Non-neoplastic from A2
5	A3	M	71	colon	Adenocarcinoma
6	B3	M	71	colon	Non-neoplastic from A3
7	A4	F	52	colon	Adenocarcinoma
8	B4	F	52	colon	Non-neoplastic from A4
9	A5	M	54	colon	Adenocarcinoma
10	B5	M	54	colon	Non-neoplastic from A5
11	A6	M	54	colon	Adenocarcinoma
12	B6	M	54	colon	Non-neoplastic from A6

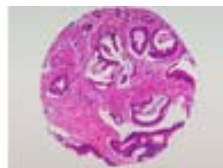QC sheet_LOT#122120403031
Hematoxylin and Eosin staining



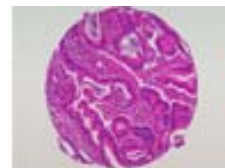
A1



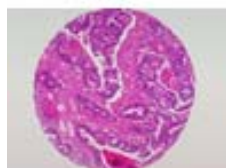
A2



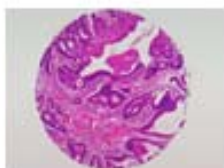A3



A4



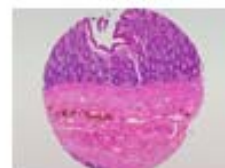A5



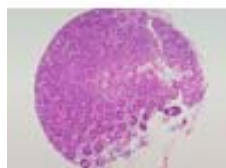
A6



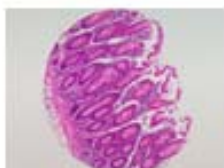B1



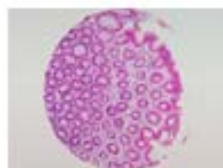B2



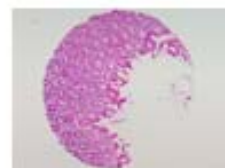B3



B4



B5



B6

A713: Test slide - Colon cancer tissues with corresponding normal

No.	Coordinate		Sex	Age	Key Word	Histological Diagnosis
1	A	1	m	76	colon	1. Sigmoid colon with pericolic fatty tissue, anterior resection: ulcerative adenocarcinoma, moderately differentiated 1) size: 3.5x3.5 cm 2) expanding growth 3) penetration of muscle layer and extension to pericolic fatty tissue 4) lymphovascular invasion 5) intact proximal and distal resection margins 6) metastasis to 1 out of 9 pericolic fatty tissue (1/9: pericolic (1/9) and principal, separately submitted (0/0))
2	B	1	m	79	colon	Non-neoplastic from, A1
3	A	2	f	75	colon	1. Colorectum with perirectal fatty tissue, resection: ulcerofungating adenocarcinoma, moderately to poorly differentiated, 1) size: 4.5x4.3 cm 2) infiltrative growth 3) extension to perirectal soft tissue and serosa 4) lymphovascular and perineural invasion 5) intact proximal, distal and perirectal lateral resection margins 6) metastasis to 7 out of 21 perirectal lymph nodes (perirectal (7/21), principal, separately submitted (0/0))
4	B	2	f	75	colon	Non-neoplastic from, A2
5	A	3	m	71	colon	1. Colon, cecum and transverse colon, right hemicolectomy: ulcerofungating adenocarcinoma, moderately differentiated, in ascending colon 1) size: 5.5x4.5 cm 2) extension to pericolic fatty tissue 3) diffuse infiltrative growth 4) perineural and lymphovascular invasion 5) intact proximal and distal resection margins 6) no metastasis to pericolic fatty tissue (0/22) 2. Liver, wedge resection: 1) metastatic adenocarcinoma 2) originated from colon, incompletely excised 3. Appendix: free from tumor extension

A713: Test slide - Colon cancer tissues with corresponding normal

No.	Coordinate		Sex	Age	Key Word	Histological Diagnosis
6	B	3	m	71	colon	Non-neoplastic from, A3
7	A	4			colon	1. Colon, ascending, appendix and ileum, right, hemicolectomy: adenocarcinoma, well differentiated, ulcerative, 1) extension to the serosal surface and occasional lymphatic invasion 2) resection margins, proximal and distal: free of tumor 3) lymph nodes, regional (2/27): metastasis in 2 out of 27 nodes 2. Appendix: no pathological diagnosis
8	B	4	f	52	colon	Non-neoplastic from, A4
9	A	5	m	49	colon	1. Colon, rectum, Miles' operation: ulcerofungating adenocarcinoma, moderately differentiated 1) extension to the pericolic fat tissue (pT3b) 2) lateral margin: free of tumor 3) lymphovascular permeation: positive 4) resection margins, proximal and distal: free of tumor 2. Regional lymph nodes: tumor metastasis to 1 out of 24 (1/24), in detail, principal (0/1), regional (1/23)
10	B	5	m	19	colon	Non-neoplastic from, A5
11	A	6	m	52	colon	1. Transverse colon, right hemicolectomy: Adenocarcinoma, moderately differentiated, ulcerofungating type 1) extension to the pericolic fat tissue 2) resection margins, proximal and distal: free of tumor. 3) lymph nodes, regional (0/21): free of tumor. 2. Appendix: no pathological diagnosis.
12	B	6	m	52	colon	Non-neoplastic from, A6